



Early Timely Treatment of Class III Malocclusion

Peter Ngan

The protraction facemask has been widely used in the treatment of Class III malocclusion with maxillary deficiencies. However, the benefit of this early treatment modality is not clear. One of the reasons orthodontists are reluctant to render early orthopedic treatment in Class III patients is the inability to predict mandibular growth. The use of a single cephalometric radiograph to predict excessive mandibular growth has severe limitations. The use of serial cephalometric radiographs taken a few years after facemask treatment, and a Growth Treatment Response Vector (GTRV) analysis to individualize and enhance the accuracy in predicting excessive mandibular growth, is presented and proposed. This article discusses the rationale for early "timely" treatment of Class III malocclusion, the indications and contraindications for early Class III treatment, and provides a method of predicting excessive mandibular growth using the GTRV analysis.

Semin Orthod 11:140-145 © 2005 Elsevier Inc. All rights reserved.

The occurrence of Class III malocclusion is believed to be hereditary although environmental factors such as habits and mouth breathing may play a role.^{1,2} The prevalence of Class III malocclusion varies among different ethnic groups. The incidence in Caucasians ranges between 1% and 4% depending on the method of classifying the malocclusion and the age group evaluated.³⁻⁵ In Asian societies, the frequency of Class III malocclusions is higher due to a large percentage of patients with maxillary deficiency. The incidence ranges between 4% and 5% among the Japanese and 4% and 14% among the Chinese.^{6,7}

Individuals with Class III malocclusion may have combinations of skeletal and dentoalveolar components. According to Guyer and coworkers, 57% of the patients with either a normal or prognathic mandible showed a deficiency in the maxilla.⁸ Protraction facemask therapy has been advocated in the treatment of Class III patients with maxillary deficiency.⁹⁻¹¹ The dental and skeletal effects of this appliance are well documented in the literature.¹²⁻¹⁶ However, one of the reasons orthodontists are reluctant to render early orthopedic treatment in Class III patients is the inability to predict mandibular growth.¹⁷ Patients who have received early orthopedic treatment could still require surgical treatment at the end of the growth period. The ability to identify Class III patients with excessive mandibular growth at an early age

could help orthodontists to plan for future orthodontic care. The use of a single cephalometric radiograph to predict mandibular growth has limitations. Discriminant analysis from long-term results of early treatment identified several cephalometric variables such as the position of the mandible, corpus length, gonial angle, and ramal height that have predictive values.¹⁸⁻²⁰ However, these predictive formulae are better in predicting successful outcomes than unsuccessful outcomes.

Rationale for Early Timely Treatment of Class III Malocclusions

The objective of early orthodontic treatment is to create an environment in which a more favorable dentofacial development can occur.²¹ The goals of early Class III treatment may include the following:

1. To prevent progressive irreversible soft tissue or bony changes. Class III malocclusion is often accompanied with an anterior crossbite. Uncorrected anterior crossbite may lead to abnormal wear of the lower incisors, dental compensation of mandibular incisors, leading to thinning of the labial alveolar plate and/or gingival recession.²²
2. To improve skeletal discrepancies and provide a more favorable environment for future growth. Excessive mandibular growth is often accompanied by dental compensation of the mandibular incisors. Early orthopedic treatment using facemask or chin cup therapy

Department of Orthodontics, School of Dentistry, West Virginia University, Morgantown, WV.

Address correspondence to Peter Ngan, DMD, Department of Orthodontics, School of Dentistry, West Virginia University, 1076 Health Science Center North, PO Box 9480, Morgantown, WV 26506. Phone: (304) 293-3222; Fax: (304) 293-2327; E-mail: pngan@hsc.wvu.edu

improves the skeletal relationships, which in turn minimize excessive dental compensation such as overclosure of the mandible and retroclination of the mandibular incisors.

3. To improve occlusal function. Class III malocclusion with an anterior crossbite is often accompanied by a functional shift. Early orthopedic treatment may help in eliminating centric occlusion/centric relation (CO/CR) discrepancies and avoid adverse growth potential.
4. To simplify phase II comprehensive treatment. In mild and moderate Class III patients, early orthodontic or orthopedic treatment may eliminate the necessity for orthognathic surgery treatment. Even if surgery is eventually needed, early correction of the transverse dimension and maximizing the growth potential of the maxilla may minimize the extent of the surgical procedures.
5. To provide more pleasing facial esthetics, thus improving the psychosocial development of a child.²³ Studies have shown that treatment with facemask and/or chin cap improves lip posture and facial appearance.^{24,25}

Indications and Contraindications for Early Class III Treatment

Turpin developed a list of positive and negative factors to aid in deciding when to intercept a developing Class III malocclusion.²⁶ The positive factors include good facial esthetics, mild skeletal disharmony, no familial prognathism, presence of anteroposterior functional shift, convergent facial type, symmetric condylar growth, and growing patients with expected good cooperation. The negative factors include poor facial esthetics, severe skeletal disharmony, familial pattern established, no anteroposterior shift, divergent facial type, asymmetric condylar growth, growth complete, and poor cooperation. Turpin recommends that early treatment should be considered for a patient that presents with positive characteristics. For individuals who present with negative characteristics, treatment can be delayed until growth is completed.²⁶ Patients should be aware that surgery may be needed at a later date, even when an initial phase of treatment may be successful.

Early Treatment of Skeletal Class III Malocclusions

Chin Cup Therapy

Skeletal malocclusion with a relatively normal maxilla and a moderately protrusive mandible may be treated with the use of a chin cup. This treatment modality is popular among the Asian population because of its favorable effects on the sagittal and vertical dimensions. The objective of early treatment with the use of a chin cup is to provide growth inhibition or redirection and posterior positioning of the mandible.

The orthopedic effects of a chin cup on the mandible include redirection of mandibular growth vertically, backward

repositioning (rotation) of the mandible, and remodeling of the mandible with closure of the gonial angle. To date, there is no agreement in the literature as to whether chin cup therapy may or may not inhibit the growth of the mandible.²⁷⁻²⁹ However, chin cup therapy has been shown to produce a change in the mandible associated with a downward and backward rotation and a decrease in the angle of the mandible.²⁸⁻³¹ In addition, there is less incremental increase in mandibular length together with posterior movement of the mandible. Because of the backward mandibular rotation of the mandible, control of vertical growth is difficult to manage, especially in long-face patients.

Chin cups are divided into two types: the occipital-pull chin cup that is used for patients with mandibular protrusion and the vertical-pull chin cup that is used in patients presenting with a steep mandibular plane angle and excessive anterior facial height. Most of the reported studies recommended an orthopedic force of 300 to 500 g per side.^{6,32,33} Patients are instructed to wear the appliance 14 hours per day. The orthopedic force is usually directed either through the condyle or below the condyle.

Evidence suggests that treatment of mandibular protrusion is more successful when it is started in the primary or early mixed dentition.^{30,32,34} The treatment time varies from 1 year to as long as 4 years, depending on the severity of the malocclusion. The stability of chin cup treatment remains unclear. Several investigators reported a tendency to return to the original growth pattern after the chin cup is discontinued.^{33,36} Sugawara and coworkers published a report on the long-term effects of the chin cup on three groups of Japanese girls who started treatment at 7, 9, and 11 years of age.³⁵ The authors found that patients who started at an early age had a catch-up mandibular displacement in a forward and downward direction before growth was completed. However, several investigators believe that early correction of anterior crossbite reinforces the horizontal growth of the maxilla and prevents deterioration of horizontal jaw relationships.^{33,34}

Protraction Facemask Therapy

The protraction facemask has been used in the treatment of patients with Class III malocclusions and a maxillary deficiency. The facemask has an adjustable anterior wire that can accommodate a downward and forward pull on the maxilla with elastics. To minimize the tipping of the palatal plane, the protraction elastics are attached near the maxillary canines with a downward and forward pull of 30° from the occlusal plane.^{11,12} Maxillary protraction usually requires 300 to 600 g of force per side, depending on the age of the patient. Patients are instructed to wear the appliance for 12 hours per day.

In the mixed dentition, a banded or bonded expansion appliance can be fabricated as anchorage for maxillary protraction. The expansion appliance is activated twice daily (0.25 mm per turn) by the patient or parent for 7 to 10 days. In patients with a more constricted maxilla, activation of the appliance is performed for 2 weeks or more.

Several facial sutures play an important role in the development of the nasomaxillary complex (frontomaxillary,

nasomaxillary, zygomaticotemporal, zygomaticomaxillary, pterygopalatine, intermaxillary, ethmomaxillary, and the lacrimomaxillary sutures). Animal studies have shown that the maxillary complex can be displaced anteriorly with significant changes in these facial sutures.³⁶⁻³⁸ Maxillary protraction, however, does not always result in forward movement of the maxilla. With the same line of force, different midfacial bones were displaced in different directions depending on the moments of force generated at the sutures.³⁸ The center of resistance of the maxilla was found to be located at the distal contacts of the maxillary first molars one half the distances from the functional occlusal plane to the inferior border of the orbit.³⁹ Protraction of the maxilla below the center of resistance produces counterclockwise rotation of the maxilla, which may not be favorable for patients with an open bite tendency.⁴⁰

Clinically, anterior crossbite can be corrected with 3 to 4 months of maxillary expansion and protraction depending on the severity of the malocclusion. Improvement in overbite and molar relationship can be expected with an additional 4 to 6 months of treatment. In a prospective clinical trial, overjet correction was found to be the result of forward maxillary movement (31%), backward movement of the mandible (21%), labial movement of the maxillary incisors (28%), and lingual movement of the mandibular incisors (20%).⁴¹ Overcorrection of the overjet and molar relationship was highly recommended in anticipation of unfavorable mandibular growth. Overbite was improved by eruption of the posterior teeth. The total facial height was increased by inferior movement of the maxilla and downward and backward rotation of the mandible.

The question arises as to when is the best time to start protraction facemask treatment. The main objective of early facemask treatment is to enhance forward displacement of the maxilla by sutural growth. It has been shown by Melsen in her histological findings that the midpalatal suture was broad and smooth during the "infantile" stage (8 to 10 years of age) and the suture became more squamous and overlapping in the "juvenile" stage (10 to 13 years).^{42,43} Clinically, studies have shown that maxillary protraction was effective in the primary, mixed as well as early permanent dentitions. Several studies suggested that a greater degree of anterior maxillary displacement can be found when treatment was initiated in the primary or early mixed dentition.^{14,44} The optimal time to intervene a Class III malocclusion is at the time of the initial eruption of the maxillary incisors. A positive overjet and overbite at the end of the facemask treatment appears to maintain the anterior occlusion. Biologically, the circummaxillary sutures are smooth and broad before age 8 and become more heavily interdigitated around puberty.⁴²

Another question is whether early treatment can sustain subsequent mandibular growth during pubertal growth spurt. In a prospective clinical trial, protraction facemask treatment starting in the mixed dentition was found to be stable 2 years after the removal of the appliances.¹² This is probably due to the overcorrection and the use of a functional appliance as retainer for 1 year. When these patients were followed for another 2 years 15 of the 20 patients maintained

a positive overjet.⁴¹ In patients who relapsed back to a negative overjet, the mandible outgrew the maxilla in the horizontal direction. When these patients were followed for another 4 years (8 years after treatment until about 17.5 years of age), 14 of 20 patients (67%) maintained a positive overjet.⁴⁵ For the patients who relapsed back into a reverse overjet, the mandible outgrew the maxilla by four times, compared with twice that in the stable group. These results suggest that in a random clinical trial when patients are followed until after completion of pubertal growth, two of three patients or 67% will have a favorable outcome. About one third of the patients might be candidates for orthognathic surgery later in life because of an unfavorable growth pattern. In an implant study, Bjork and Skieller examined the normal and abnormal growth of the mandible found that condylar growth does not follow a circular or logarithmic spiral course.⁴⁷ It is characterized by individual variations both in the rate and growth direction. In addition, the rotation of the maxilla also varied from child to adulthood. This then raises the question as to whether it is possible to predict excess mandibular growth.

Growth Prediction of Class III Malocclusion

Several investigators have attempted to predict the progression of Class III malocclusions.^{18,20,31,47-49} Schulhof and associates compared several morphological characteristics of Class III patients with the norm (molar relationship, cranial deflection, porion location, and ramus positions).⁴⁷ Using the Rocky Mountain Data System⁴⁷ (Sherman Oaks, CA), if the sum of the deviations is greater than four, the computer warns the orthodontist of excessive mandibular growth. The accuracy of prediction is around 70% to 80%. Mito and coworkers suggested the use of cervical vertebral bone age to predict mandibular growth potential.⁴⁸ The authors noted that this method is only useful in skeletal Class I patients with average growth pattern. Discriminant analysis of long-term results of early treatment identified several variables that had predictive values. Franchi and coworkers found the inclination of the condylar head, the maxillomandibular vertical relationship together with the width of the mandibular arch, could predict success or failure of early treatment.¹⁸ Ghiz and coworkers found that the position of the mandible, the ramal length, the corpus length, and the gonial angle can predict successful outcomes with 95% degree of accuracy.²⁰ However, using a single cephalogram, the prediction formula can only accurately diagnose unsuccessful cases with only a 70% degree of accuracy. The present author proposes the use of serial cephalometric radiographs of patients taken a few years apart after facemask treatment and the use of a Growth Treatment Response Vector analysis to individualize and enhance the success of predicting excessive mandibular growth in Class III patients. The diagnostic procedure is usually performed during the early mixed dentition once a patient is diagnosed with maxillary deficiency. The patient will then be treated with maxillary expansion and a protraction facemask to eliminate the anterior crossbite, CO/CR discrepancy, and

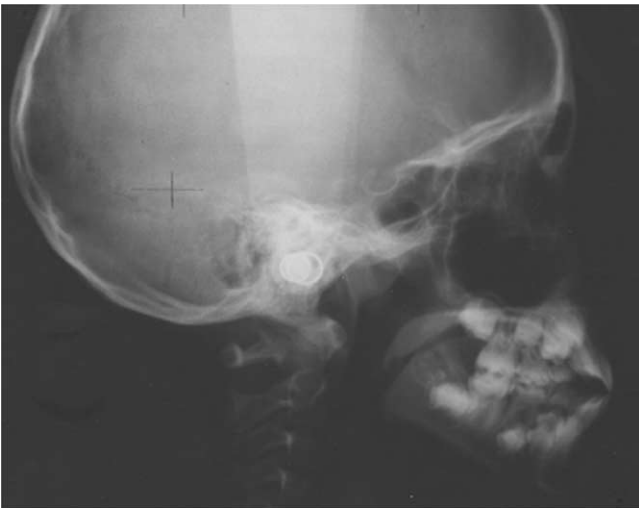

Figure 1 Lateral cephalometric radiograph of patient with Class III malocclusion immediately after protraction facemask treatment.

maximize the growth potential of the nasomaxillary complex. The patient is followed for 3 to 4 years for growth observation. A GTRV analysis will then be performed during the early permanent dentition to allow clinicians to decide whether the malocclusion can be camouflaged by orthodontic treatment or whether a surgical intervention is necessary when growth is completed.

Growth Treatment Response Vector (GTRV) Analysis

Patients who presented with a Class III malocclusion and maxillary deficiency were treated with maxillary expansion and protraction facemask to eliminate anterior crossbite, CO/CR discrepancy, and maximize the growth potential of the nasomaxillary complex. Lateral cephalometric radiographs were taken after facemask treatment (Fig 1) and during the 3- to 4-year follow-up visit (Fig 2). The horizontal growth changes of the maxilla and mandible between the posttreatment radiograph and the follow-up radiograph are

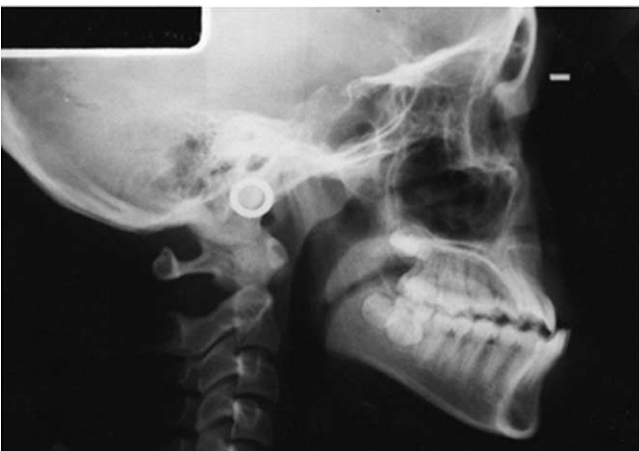

Figure 2 Lateral cephalometric radiograph of the same patient 3.8 years following protraction facemask treatment.

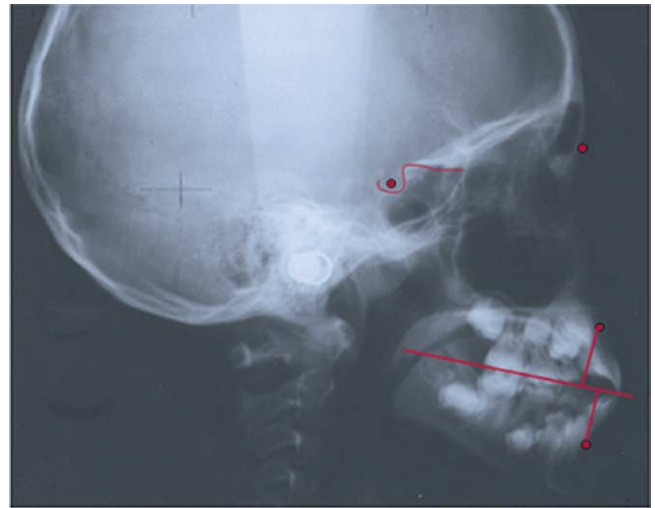


Figure 3 The horizontal growth changes of the maxilla and the mandible between the posttreatment radiograph and the follow-up radiograph were determined by locating the A point and B point on the first radiograph. The occlusal plane (O) was constructed by using the mesial buccal cusp of the maxillary molars and the incisal tip of the maxillary incisors as landmarks. The line AO and BO were then constructed by connecting A and B point perpendicular to the occlusal plane.

determined by locating the A point and B point on the post-treatment radiograph (Fig 3). The occlusal plane (O) is constructed by using the mesial buccal cusp of the maxillary molars and the incisal tip of the maxillary incisors as landmarks. The lines AO and BO are then constructed by connecting point A and B perpendicular to the occlusal plane similar to the “Wits” analysis.⁴⁹

The first tracing is superimposed on the follow-up radiograph using the stable landmarks on the midsagittal cranial structure⁴⁶ (Fig 4). The A point and B point on the follow-up radiograph are located and the lines AO and BO are then constructed by connecting point A and point B of the follow-up radiograph to the occlusal plane of the first tracing. The distance between the A point of the two tracings along the occlusal plane represented the growth changes of the maxilla and the distance on the occlusal plane of the B point of the two tracings represented the growth changes of the mandible.

The GTRV ratio was calculated by using the following formula:

$$\text{GTRV} = \frac{\text{Horizontal growth changes of the maxilla}}{\text{Horizontal growth changes of the mandible}}$$

The arrows show the growth vector of the maxilla and the mandible after facemask treatment (Fig 4). Clinicians can compare the growth changes of their Class III patients with the normal skeletal growth pattern derived from the Bolton Growth Study (Fig 5). The GTRV ratio of an individual with normal growth pattern from age 8 to 16 is calculated to be 0.77. That means the mandible usually exceed the maxilla in horizontal growth by 23% to maintain a good skeletal rela-

tionship. What about in patients with Class III growth pattern?

A study on 20 patients who were successfully treated with facemask therapy and 20 patients who were unsuccessfully treated with facemask therapy indicated that the GTRV ratio of the successful and unsuccessful groups were significantly different from each other ($P < 0.05$).⁵⁰ The mean GTRV ratio for the successful group was 0.49 ± 0.14 with a range of 0.33 to 0.88. The mandible outgrew the maxilla by 51% during this observation period compared with 23% for individuals with normal skeletal growth pattern. The mean GTRV ratio for the unsuccessful group was 0.22 ± 0.10 with a range of 0.06 to 0.38. The mandible exceeded the maxilla in growth by 78% compared with 23% for individuals with normal skeletal growth pattern. These results suggest that Class III patients with maxillary deficiency and a GTRV ratio that falls between 0.33 and 0.88 can be successfully camouflaged with orthodontic treatment. Class III patients with excessive mandibular growth together with a GTRV ratio that falls below 0.38 should be warned of the future need for orthognathic surgery.

Conclusions

It has been shown that in a random clinical trial when patients are followed until after completion of pubertal growth, one out of three patients may be candidates for orthognathic surgery later in life because of an unfavorable growth pattern. Early treatment of Class III patients with maxillary deficiency using appliances such as the protraction facemask can be used to eliminate anterior crossbite, CO/CR discrepancy, and maximize the growth potential of the nasomaxillary complex. In addition, it can be used together with the GTRV analysis as a tool to help clinicians in predicting patients with excessive mandibular growth that may not be able to be camouflaged

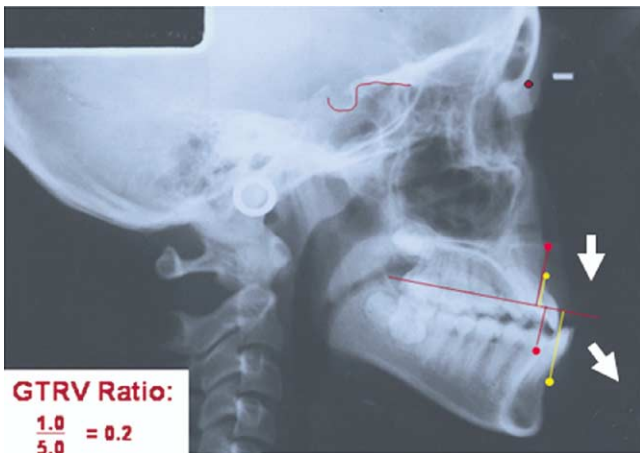


Figure 4 The first tracing was superimposed on the follow-up radiograph by using the stable landmarks on the midsagittal cranial structure. The distance between the A point of the two tracings along the occlusal plane represented the growth changes of the maxilla and the distance on the occlusal plane of the B point represented the growth changes of the mandible. GTRV ratio was then calculated by using the formula as depicted in the text.

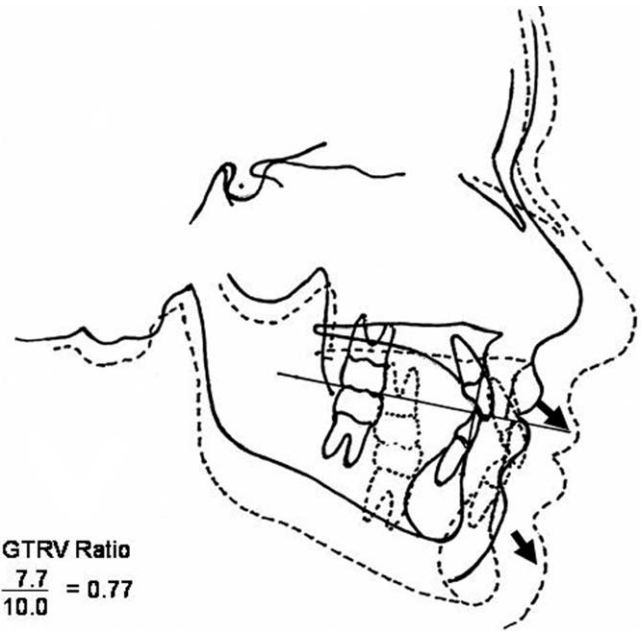


Figure 5 Growth changes of a patient with normal skeletal pattern from age 8 to age 16 derived from the Bolton Growth Study to illustrate the GTRV ratio and growth vectors of a patient with a normal skeletal pattern.

with orthodontic treatment. Protraction facemask treatment is ideally performed in the early mixed dentition. A follow-up lateral cephalogram can be taken 2 to 3 years after completion of protraction facemask treatment to determine the horizontal growth of the maxilla and the mandible as well as the growth vector or direction. The Growth Treatment Response Vector (GTRV) ratio calculated during the early permanent dentition period will allow clinicians to inform patients whether malocclusion can be camouflaged with orthodontic treatment or if surgical treatment will be required at a later age.¹⁰

References

1. Litton SF, Ackermann LV, Isaacson RJ, et al: A genetic study of Class III malocclusion. *Am J Orthod* 58:565-577, 1970
2. Rokosi T, Schilli W: Class III anomalies: a coordinated approach to skeletal, dental, and soft tissue problems. *J Oral Surg* 39:860-870, 1981
3. Newman GV: Prevalence of malocclusion in children 6-14 years of age and treatment in preventable cases. *Am J Dent Assoc* 52:566-575, 1956
4. Thilander B, Myrberg N: The prevalence of malocclusion in Swedish school children. *Scand J Dent Res* 81:12-20, 1973
5. Tschill P, Bacon W, Sonko A: Malocclusion in the deciduous dentition of Caucasian children. *Eur J Orthod* 19:361-367, 1997
6. Ishii H, Morita S, Takeuchi Y, et al: Treatment effect of combined maxillary protraction and chin cap appliance in severe skeletal Class III cases. *Am J Orthod Dentofacial Orthop* 92:304-312, 1987
7. Allwright WC, Burndred WH: A survey of handicapping dentofacial anomalies among Chinese in Hong Kong. *Int Dent J* 14:505-519, 1964
8. Guyer EC, Ellis EE, McNamara JA, et al: Components of Class III malocclusions in juveniles and adolescents. *Angle Orthod* 56:7-30, 1986
9. Turley P: Orthopedic correction of Class III malocclusion with palatal expansion and custom protraction headgear. *J Clin Orthod* 5:314-325, 1988
10. McNamara JA: An orthopedic approach to the treatment of Class III malocclusion in young patients. *J Clin Orthod* 9:598-608, 1987

11. Ngan P, Wei SHY, Hagg U, et al: Effects of headgear on Class III malocclusion. *Quintessence Int J* 23:197-207, 1992
12. Ngan P, Yiu C, Hu A, et al: Cephalometric and occlusal changes following maxillary expansion and protraction. *Eur J Orthod* 20:237-254, 1998
13. Nartallo-Turley PE, Turley P: Cephalometric effects of combined palatal expansion and facemask therapy on Class III malocclusion. *Angle Orthod* 68:217-224, 1998
14. Baccetti T, McGill JS, Franchi L, et al: Skeletal effects of early treatment of Class III malocclusion with maxillary expansion and facemask therapy. *Am J Orthod Dentofacial Orthop* 113:333-343, 1998
15. Baik HS: Clinical results of the maxillary protraction in Korean children. *Am J Orthod Dentofacial Orthop* 108:583-592, 1995
16. da Silva Filho OG, Magro AC, Capiozza Filho L: Early treatment of the Class III malocclusion with rapid maxillary expansion and maxillary protraction. *Am J Orthod Dentofacial Orthop* 113:196-203, 1998
17. Ngan P: Biomechanics of maxillary expansion and protraction in Class III patients. *Am J Orthod Dentofacial Orthop* 121:582-583, 2002
18. Franchi L, Baccetti T, Tollaro L: Predictive variables for the outcome of early functional treatment of Class III malocclusion. *Am J Orthod Dentofacial Orthop* 112:80-86, 1997
19. Tahmina K, Tanaka E, Tanne K: Craniofacial morphology in orthodontically treated patients of class III malocclusion with stable and unstable treatment outcomes. *Am J Orthod Dentofacial Orthop* 117:681-690, 2000
20. Ghiz M, Ngan P, Gunel E: Cephalometric variables to predict future success of Class III orthopedic treatment [abstract 1158]. *J Dent Res* 80:180, 2001
21. Joondeph DR: Early orthodontic treatment. *Am J Orthod Dentofacial Orthop* 104:199-200, 1993
22. Ngan P: Treatment of Class III malocclusion in the primary and mixed dentitions, in Bishara SE (ed): *Textbook of Orthodontics*. Philadelphia, PA, WB Saunders, 2001, pp 375-411
23. O'Brien K, Wright J, Conboy F, et al: Effectiveness of early orthodontic treatment with the twin-block appliance: multicenter, randomized, controlled trial. Part 2: Psychosocial effects. *Am J Orthod Dentofacial Orthop* 124:488-494, 2003
24. Ngan P, Hagg U, Merwin D, et al: Soft tissue and dentoskeletal profile changes associated with maxillary expansion and protraction headgear treatment. *Am J Orthod Dentofacial Orthop* 109:38-49, 1996
25. Kilicoglu H, Kirlic Y: Profile changes in patients with Class III malocclusions after Delaire mask therapy. *Am J Orthod Dentofacial Orthop* 113:453-462, 1998
26. Turpin DL: Early Class III treatment. Unpublished thesis presented at 81st session of the American Association of Orthodontists, San Francisco, 1981
27. Sakamoto T, Iwase I, Uka A, et al: A roentgenocephalometric study of skeletal changes during and after chin cup treatment. *Am J Orthod* 85:341-350, 1984
28. Wendell PD, Nanda R, Sakamoto T, et al: The effects of chin cup therapy on the mandible: a longitudinal study. *Am J Orthod* 87:265-274, 1985
29. Mitani H, Fukazawa H: Effects of chin cup force on the timing and amount of mandibular growth associated with anterior reverse occlusion (Class III malocclusion) during puberty. *Am J Orthod Dentofacial Orthop* 9:454-463, 1986
30. Graber LW: Chin cup therapy for mandibular prognathism. *Am J Orthod* 72:23-41, 1977
31. Ko YI, Baek SH, Mah J, et al: Determinants of successful chin cup therapy in skeletal Class III malocclusion. *Am J Orthod Dentofacial Orthop* 126:33-41, 2004
32. Uner O, Yuksel S, Ucuncu N: Long-term evaluation after chin cup treatment. *Eur J Orthod* 17:135-141, 1995
33. Deguchi T, Kitsugi A: Stability of changes associated with chin cup treatment. *Angle Orthod* 66:139-146, 1996
34. Mitani H: Early application of chin cup therapy to skeletal Class III malocclusion. *Am J Orthod Dentofacial Orthop* 121:584-585, 2002
35. Sugawara J, Asano T, Endo N, et al: Long-term effects of chin cup therapy on skeletal profile in mandibular prognathism. *Am J Orthod Dentofacial Orthop* 98:127-133, 1990
36. Kamabara T: Dentofacial changes produced by extraoral forward force in Macaca Irus. *Am J Orthod* 71:249-277, 1997
37. Jackson GW, Kokich VG, Shapiro PA: Experimental and postexperimental response to anteriorly directed extraoral force in young Macaca nemestrina. *Am J Orthod* 75:318-333, 1979
38. Nanda R: Protraction of maxilla in rhesus monkeys by controlled extraoral forces. *Am J Orthod* 74:121-141, 1978
39. Braun S: Extraoral appliances: a twenty-first century update. *Am J Orthod Dentofacial Orthop* 125:624-629, 2004
40. Hata S, Itoh T, Nakagawa M, et al: Biomechanical effects of maxillary protraction on the craniofacial complex. *Am J Orthod Dentofacial Orthop* 91:305-311, 1987
41. Ngan P, Hagg U, Yiu C, et al: Treatment response and long-term dentofacial adaptations to maxillary expansion and protraction. *Semin Orthod* 3:255-264, 1997
42. Melsen B, Melsen F: The postnatal development of the palatomaxillary region studied on human autopsy material. *Am J Orthod* 82:329-342, 1982
43. Melsen B: Palatal growth studied on human autopsy material: a histologic microradiographic study. *Am J Orthod* 68:42-54, 1975
44. Kapust A, Sinclair P, Turley P: Cephalometric effects of facemask/expansion therapy in Class III children: a comparison of three age groups. *Am J Orthod* 113:204-212, 1998
45. Hagg U, Tse A, Bendeus M, et al: Long-term follow-up of early treatment with reverse headgear. *Eur J Orthod* 25:95-102, 2003
46. Bjork A, Skieller V: Normal and abnormal growth of the mandible: a synthesis of longitudinal cephalometric implant studies over a period of 25 years. *Eur J Orthod* 5:1-46, 1983
47. Schulhof RJ, Nakamura S, Williamson WV: Prediction of abnormal growth in Class III malocclusions. *Am J Orthod* 71:421-430, 1977
48. Mito T, Sato K, Mitani H: Predicting mandibular growth potential with cervical vertebral bone age. *Am J Orthod Dentofacial Orthop* 124:173-177, 2003
49. Jacobson A: The "Wits" appraisal of jaw disharmony. *Am J Orthod* 67:125-138, 1975
50. Ngan P, Wei SHY: Early treatment of Class III patients to improve facial aesthetics and predict future growth. *Hong Kong Dent J* 1:24-30, 2004