



# Early Timely Management of Ectopically Erupting Maxillary Canines

Peter Ngan\*, Robert Hornbrook<sup>†</sup>, and Bryan Weaver<sup>‡</sup>

**Diagnosis and treatment of ectopically erupting permanent maxillary canines require timely management by the orthodontist. Potentially impacted maxillary canines may be inadvertently overlooked in the mixed dentition due to the variations in eruption patterns and timing. Periodic examination starting at age 8, including clinical intraoral palpation and selective radiographs, may aid in the early diagnosis of unerupting and potentially impacted permanent canines. When such a diagnosis is apparent, timely interceptive therapy may then be instituted. This article reviewed the incidence, etiology, and development of the maxillary canine. The rationale for early management of potentially impacted maxillary canine is discussed together with the treatment for labially and palatally impacted canines. Semin Orthod 11:152–163 © 2005 Elsevier Inc. All rights reserved.**

Diagnosis and treatment for ectopically erupting permanent maxillary canines is a clinical problem requiring triage and coordination of care by the general dentist, pediatric dentist, oral surgeon, periodontists, and the orthodontist. Maxillary canines that are potentially impacted may be inadvertently overlooked in the mixed dentition patient. This is due to individual variations in eruption patterns and timing. Periodic panoramic and selective periapical radiographs along with a careful clinical examination that includes intraoral palpation permits early diagnosis of unerupted, ectopic, and potentially impacted permanent canines. When such a diagnosis is apparent, timely interceptive therapy may then be instituted.

## Incidence

Pseudoanodontia or impacted teeth occurs most frequently with mandibular third molars, followed by maxillary canines and less frequently by premolars and mandibular canines.<sup>1</sup> In a study of 3874 routine full mouth radiographs of patients over the age of 20, Dachi and Howell<sup>2</sup> found 16.7% had at least one impacted tooth. The incidence of impacted maxil-

lary and mandibular third molars were found to be approximately 22% and 18%, respectively. Impacted maxillary canine was reported to be 0.92% and most of these were found to be unilateral. The occurrence was two times more frequent among females (1.17%) than males (0.51%). The next most commonly impacted permanent tooth was the mandibular premolar (0.4%), followed by the maxillary premolar (0.13%) and the mandibular canine (0.09%). This order is in contrast to that reported by Moyers, who stated that the teeth most frequently found to be impacted were the mandibular third molar, maxillary cuspid, maxillary third molar, mandibular and maxillary second bicuspid and the maxillary central incisor, in that order.<sup>3</sup> Thilander and Myrberg found that impacted maxillary canines occur in approximately 2.0% of the general population and mandibular canine impactions in approximately 0.2%.<sup>4</sup> Rohrer reported the incidence of permanent canine impactions to be 20 times higher in the maxilla than in the mandible.<sup>5</sup> Among patients having maxillary canine impactions, palatally displaced canines occur three times more frequently than those found buccally.<sup>4,6,7</sup> Hitchen<sup>8</sup> and Rayne<sup>9</sup> found that palatal impactions account for 85% and labial impactions 15%.

## Etiology

Canine impactions are believed to occur with a wide variety of systemic and local etiologies (Table 1).<sup>10</sup> No single etiology has been shown to explain the occurrence of a majority of impactions or to allow differential explanation of those occurring either labially or palatally. Environmental factors may contribute to this anomaly during the long, tortuous eruption path of a

\*Department of Orthodontics, School of Dentistry, West Virginia University, Morgantown, WV.

<sup>†</sup>Department of Periodontics, School of Dentistry, West Virginia University, Morgantown, WV.

<sup>‡</sup>Department of Oral and Maxillofacial Surgery, School of Dentistry, West Virginia University, Morgantown, WV.

Address correspondence to Peter Ngan, DMD, Department of Orthodontics, West Virginia University, School of Dentistry, 1076 Health Science Center North, PO Box 9480, Morgantown, WV 26506. Phone: (304) 293-3222; Fax: (304) 293-2327; E-mail: pngan@hsc.wvu.edu

**Table 1** Etiologic Factors of Impacted Canines

Genetics	Local Environmental	Systemic Environmental
Heredity	Prolonged retention of primary teeth	Endocrine deficiency
Malposed tooth germ	Reduced root length of adjacent lateral incisor	Febrile diseases
Shortened arch length	Ankylosis of permanent canine	
Alveolar cleft	Degree of dental crowding and spacing	
	Failure of primary canine root to resorb	
	Small or congenitally missing lateral incisors	

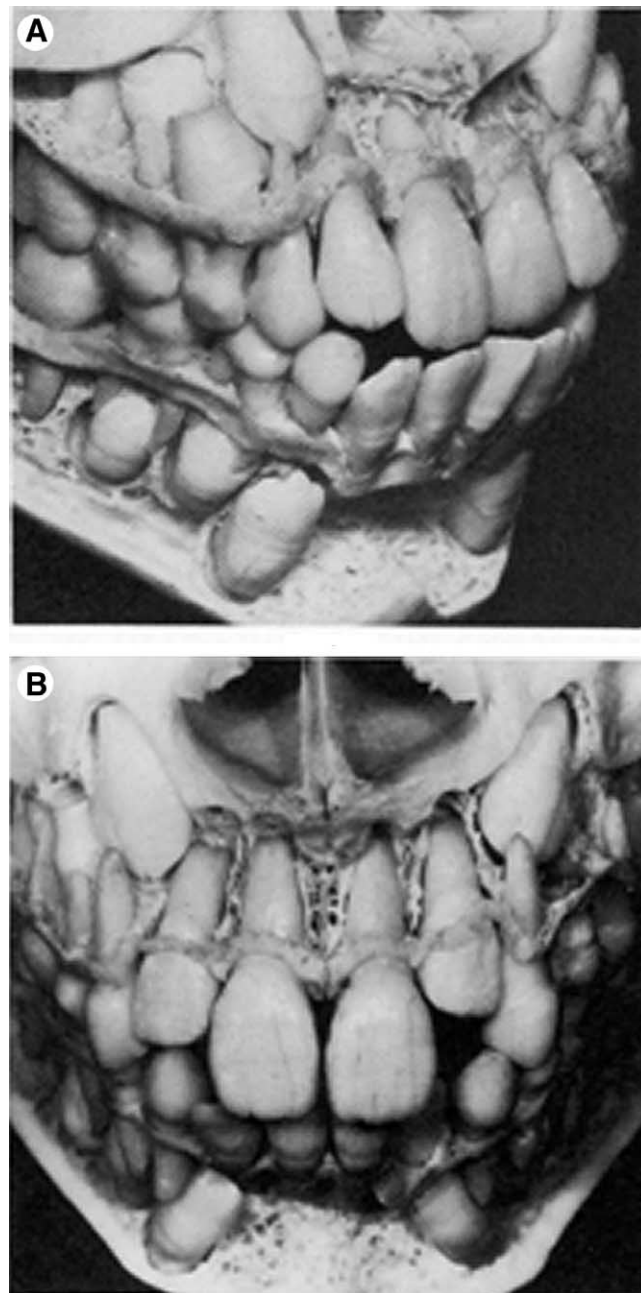
canine. Another possible explanation is that a disturbance associated with the follicle of the unerupted tooth may influence the direction of eruption and contribute to the displacement of the maxillary canine.<sup>11</sup> Jacoby<sup>12</sup> cites clinical observations in which of 46 maxillary unerupted canines requiring surgical exposure for orthodontic traction, 40 were palatally placed and 6 were labial. Of these he states 85% of the palatally impacted canines had sufficient space for eruption in the dental arch. He also stated that it is impossible to imagine that in an arch length deficiency and maxillary canine will “jump” on the lingual side, behind the lateral incisor or the first premolar. The maxillary canine is surrounded by the nasal cavity, the orbit, and the anterior wall of the sinus, located in contact with the crowns and the roots of the lateral incisor, the first premolar, and the deciduous canine. Thus, if the maxillary canine is impacted due to arch length deficiency, it can only be on the labial side because developmentally it is labially posed. Jacoby further suggested that the explanation for palatal impaction could be excessive space in the canine area.<sup>12</sup> This excessive space would allow the canine to move palatally in the bone and find a place behind the buds of the other teeth. Miller reported a high incidence of impacted canines associated with small, peg-shaped lateral incisors.<sup>13</sup> Becker and coworkers suggested that canine impaction can be explained by the lack of guidance for the roots of the lateral incisors during the early stages of canine eruption.<sup>14</sup> On the other hand, canine impactions were found to occur in families, suggesting a genetic or familial pattern of inheritance. Peck and Peck suggested a multifactorial genetic pattern of inheritance for the anomaly.<sup>15</sup>

## Development of the Dentition

The relative position of the developing permanent canines can be seen in the dissected skull of an 8-year-old child (Fig 1A and B). The maxillary canine is shown in its normal eruptive position superior to its predecessor, angulated medially with its crown lying distal and slightly buccal to the lateral incisor.<sup>16</sup> The canine

follows a mesial path until it reaches the distal aspect of the lateral incisor root. The erupting canine is gradually uprighting to a more vertical position and is guided by the lateral incisor root until it is fully erupted adjacent to the root. If the lateral incisors are congenitally missing, the canine may erupt in a mesial direction until it comes into contact with the distal aspect of the central incisor root and erupts into the lateral incisor space.<sup>17</sup>

Table 2 shows the calcification and eruption table of the maxillary and mandibular canines according to Brand and Issel-



**Figure 1** Relative position of the developing maxillary canine in the dissected skull of an 8-year-old child. (A) Lateral view. (B) Anterior view (reprinted from Van der Linden PGM: Transition of the Human Dentition. Monograph #13, Craniofacial Growth Series. Ann Arbor, MI, Center for Human Growth and Development, University of Michigan, 1982; p 80, Fig 5.4C, and p 104, Fig 6.2B).

**Table 2** Calcification and Eruption of Maxillary Canines

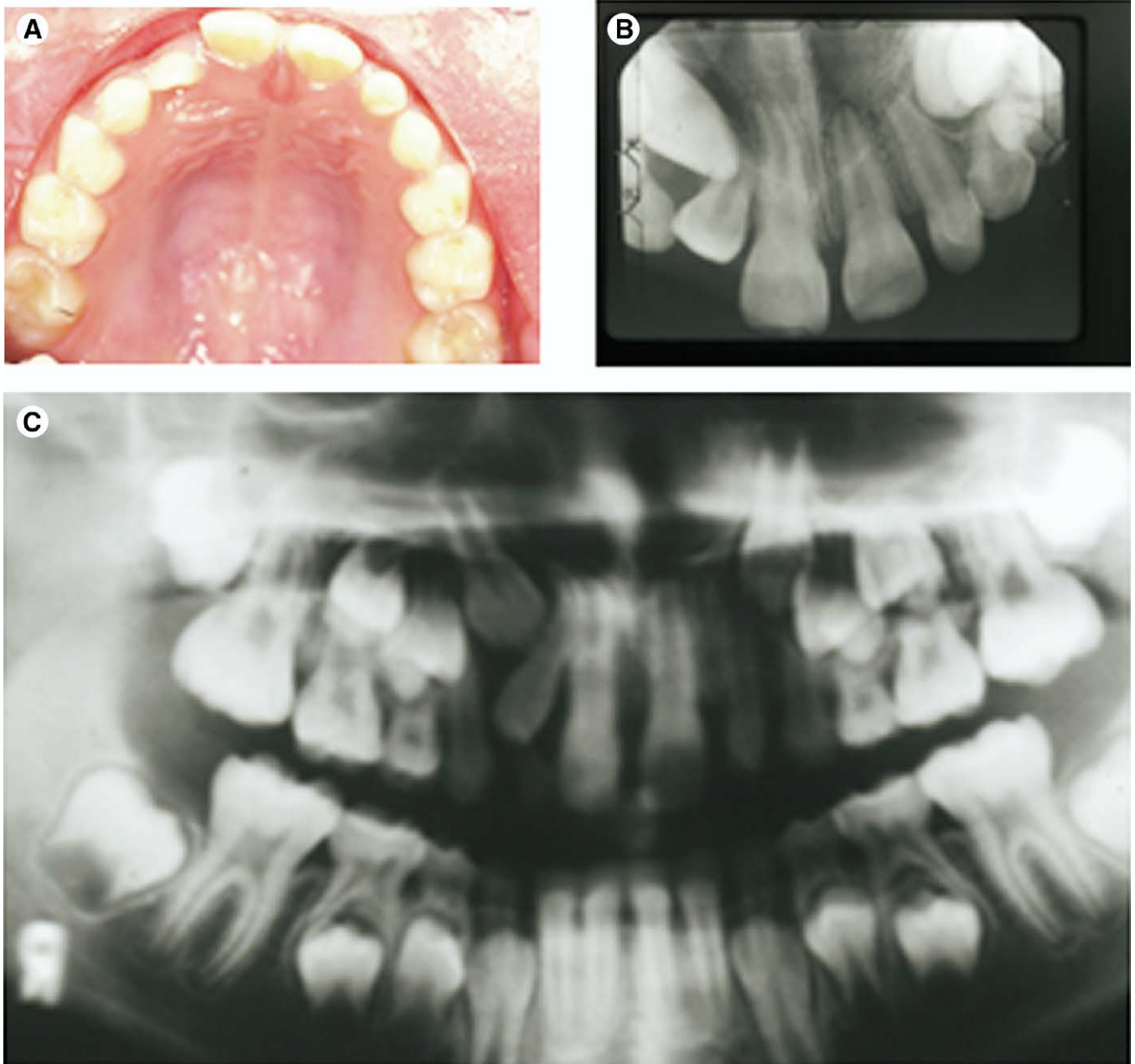
	<b>Maxillary Canines</b>
Calcification begins	4 months
Enamel complete	6-7 years
Eruption	11-12 years
Root completed	13-15 years

hard.<sup>18</sup> Studies conducted at the Forsyth Dental Infirmary showed the mean eruption age for the maxillary canine to be approximately 1 year earlier in females (10.98 years) than in males (11.69 years). Hurme believes the eruption of the maxillary canine may be considered late if it has not appeared by the

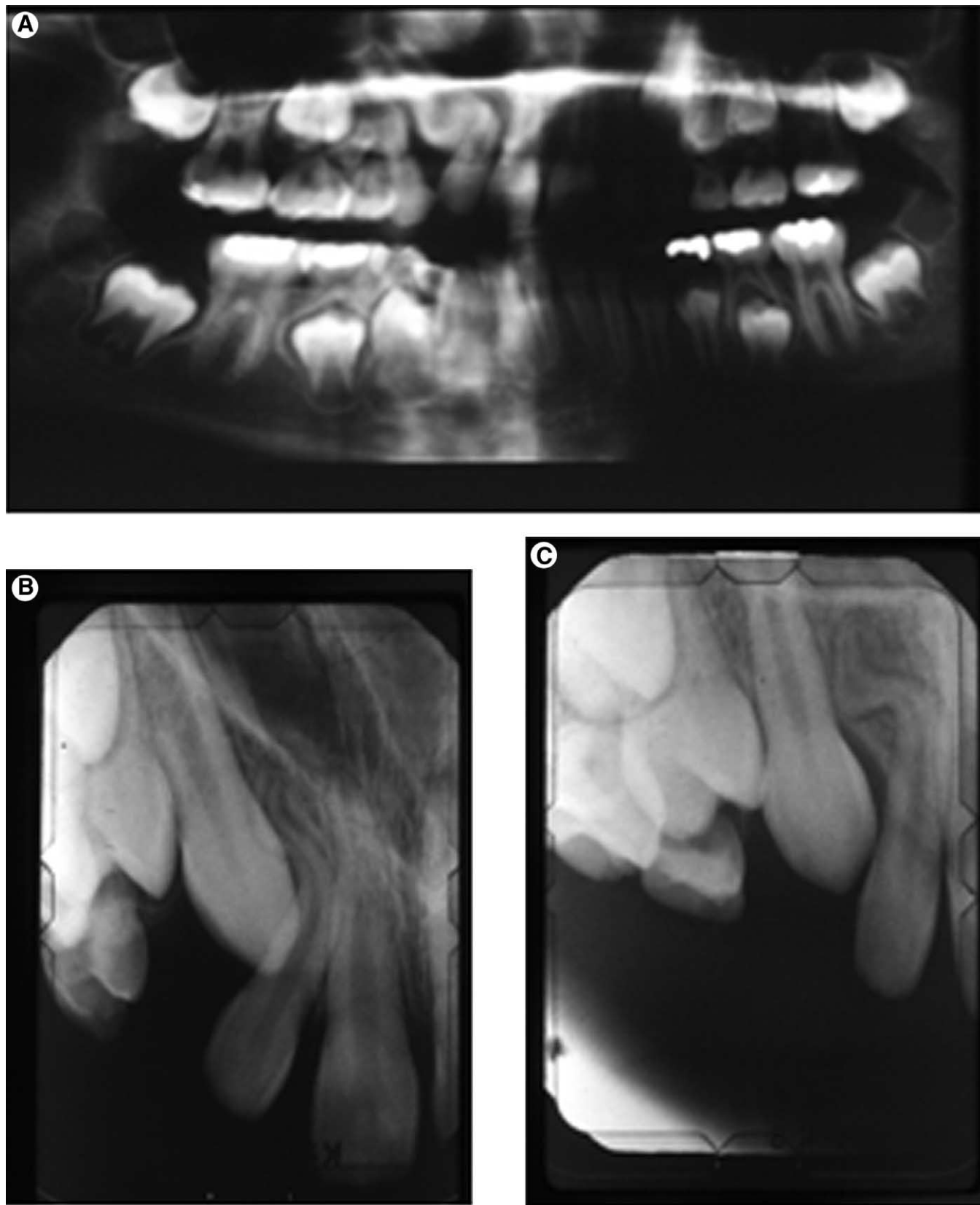
age of 13.1 in males or by 12.3 in females.<sup>19</sup> Leivesley believes that maxillary canines can be palpated and viewed, giving a general assessment of the position and angulation of eruption.<sup>20</sup> However, Power and Short stated that because there is often a poor correlation between chronologic age and dental age, overall dental development should include an understanding that the permanent teeth are almost three quarters complete before eruption into the mouth commences.<sup>21</sup>

## Diagnosis

Diagnosis of permanent canine eruption irregularities begins with clinical observations of the patient. The first sign of

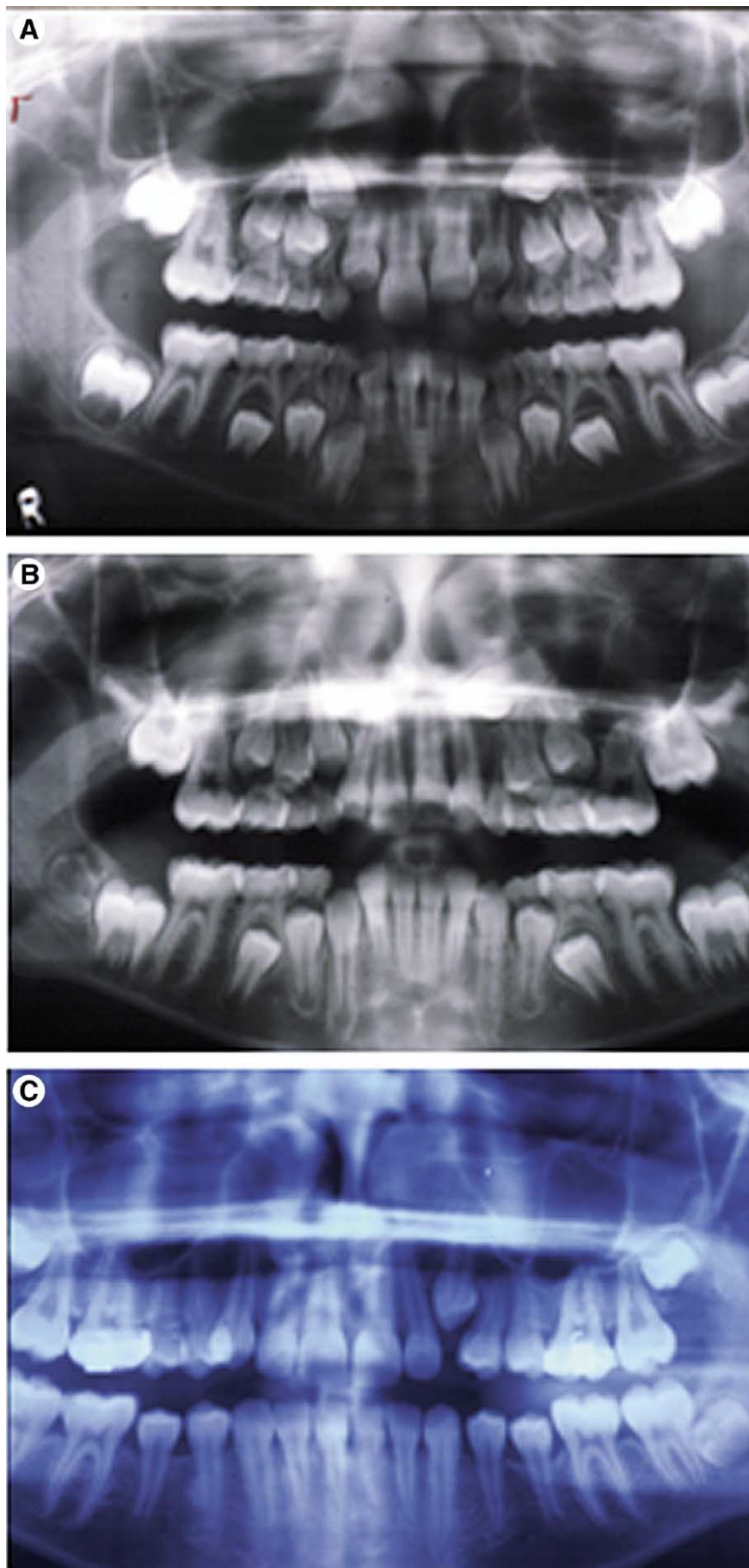


**Figure 2** (A) Eight-year-old child presenting with spacing in the maxillary incisors. (B) Occlusal film showing mesial angulation of the maxillary right permanent canine compare with the left canine. (C) Panoramic radiograph showing mesial angulation of the maxillary right permanent canine and distal crown angulation of the lateral incisor.

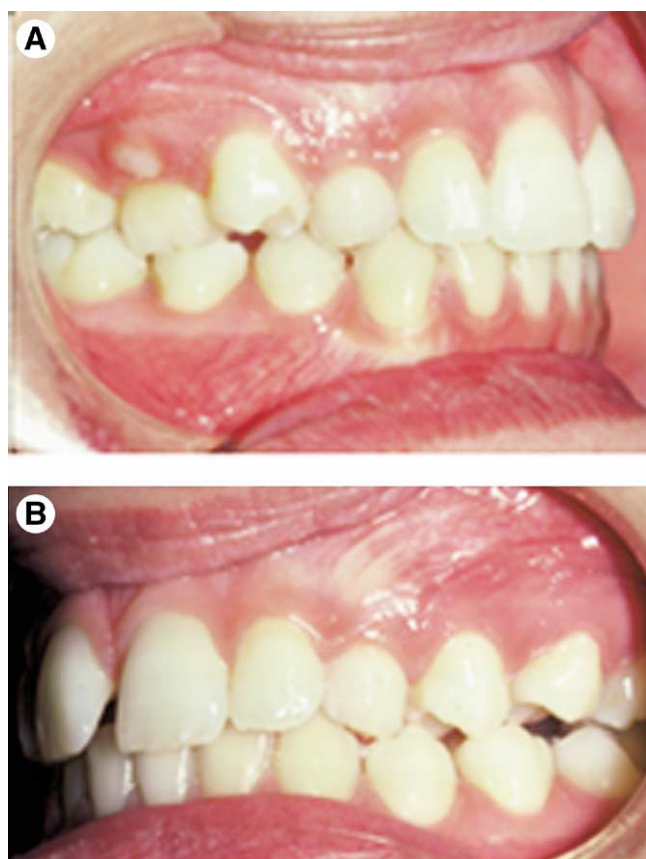


**Figure 3** (A) Same patient 2 years later showing maxillary right permanent canine has crossed the lateral border of the lateral incisor. (B) Same patient 2 years later showing improvement of the path of eruption of the maxillary canine after extraction of the primary canine. (C) Progress periapical radiograph showing small lateral incisor with dilacerated root may be the etiology of the impacted canine.





**Figure 4** (A) Six-year-old patient with abnormal angulation of the developing maxillary left canine. (B) Same patient 1 year later with no improvement in the path of eruption of the maxillary left canine. (C) Same patient 3 years after extraction of the maxillary left primary canine to facilitate the eruption of the permanent canine.



**Figure 5** A 14-year-old patient with delayed eruption of permanent teeth and bilaterally impacted maxillary canines. (A) Right lateral view. (B) Left lateral view.

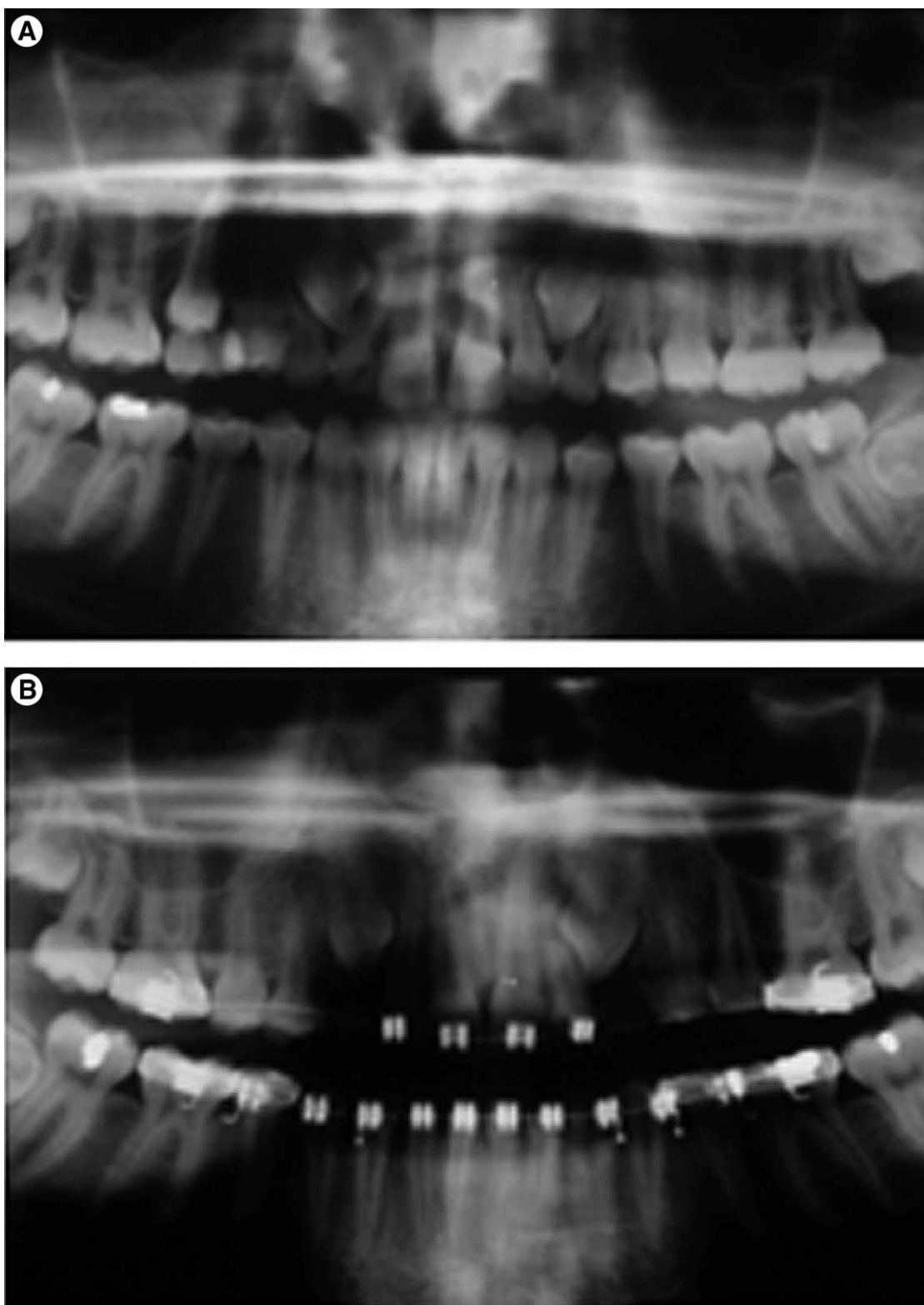
ectopic eruption is seeing unerupted permanent canines when a patient's dental development appears average relative to the chronologic age (Table 2). According to Moss, the following must be considered during clinical evaluation of the patient: (1) the amount of space in the arch for the unerupted canine, (2) the morphology and position of the adjacent teeth, (3) the contours of the bone, (4) the mobility of teeth, and (5) the radiographic assessment to determine the position of the canine; its apex, crown, and direction of longitudinal axis.<sup>22</sup>

The amount of space in the dental arch for an unerupted canine can be assessed by performing a space analysis with a full set of orthodontic records. Space for the unerupted canine can be gained by expansion of the maxillary arch, proclination of maxillary incisors, or extraction of the permanent premolars. The morphology and position of the adjacent lateral incisors can provide diagnostic information on the potentially impacted canine. Lateral incisors are often peg-shaped or undersized adjacent to impacted maxillary canines. During normal eruption of the maxillary canine, maxillary lateral incisors will appear to be flared with their crowns tipped distally. This is a result of the canine pressing on the lateral incisor root. On visual inspection, the operator will usually see a labial bulge to the mucosa superior to the maxillary primary canine. When no such bulge is visible, intraoral palpation may provide more definitive localization for the permanent canine. Bony contours often reveal une-

rupted canine positions. When palpation does not provide any positive positional information, the operator should take additional radiographs to assess the position of the potentially impacted canine. During palpation of the intraoral structures, the operator should also assess the mobility of all the teeth present. Mobile deciduous canines may indicate normal resorption of the roots by the permanent successor. However, mobility of the permanent lateral incisor may indicate potential root resorption by the impacted canine.

Radiographic analysis should begin with routine periapical radiographs. A series of such radiographs utilizing Clark's technique of horizontally moving the tube head while maintaining the film position is useful in determining whether an unerupted tooth is located to the buccal or to the lingual of other teeth in the alveolus.<sup>23,24</sup> This is sometimes called the S.L.O.B. technique, an acronym for the Same Lingual–Opposite Buccal, meaning that the object closest to the film will move in the same direction as the tube head. However, intraoral radiographic analysis has limitations for certain patients. Ericson and Kurol, in a longitudinal study of 505 children ages 8 to 12, found 41 children with indications of possible disturbance of canine eruption after initial clinical palpation.<sup>25</sup> When these patients were followed for 2.5 to 3.0 years, utilizing periapical and tomographic techniques, they found that a difference in palpation between the two sides was only a strong indicator of abnormal eruption in the children over the age of 10 years. The study found many of the children under 10 years of age whose canines initially were determined by palpation to be potentially aberrant, actually later developed and erupted normally. Early radiographic examination was thus determined to be unnecessary and impractical for children under 10 years of age.

Williams, on the other hand, believes that observation of intrabony movement of the maxillary permanent canine should begin at the dental age of 8 to 10 years.<sup>26</sup> He specifically feels that for Class I malocclusions where permanent canine bulges are not palpable, even with minimal arch length loss, lateral and frontal radiographs should be taken. He states that a medial tilt of the long axis of the cuspid in relation to the lateral wall of the nasal cavity on the frontal radiograph and a position apparently lingual to the anteriors on the lateral radiograph suggests serious consideration of the removal of the deciduous canine. Ngan and coworkers,<sup>27</sup> Moss,<sup>22</sup> and Ericson and Kurol<sup>28</sup> have demonstrated the use of occlusal radiographs to detect impacted canines. These radiographs may be an important supplement to the periapical films especially when treating an uncooperative child, a child with very small alveolar development, or one with a small oral aperture. Alone, however, this type of radiograph provides no information relative to the vertical position of the unerupted tooth. Panoramic radiography has also been utilized as a diagnostic tool for determination of unerupted canine positions. Lindauer and coworkers,<sup>29</sup> using similar techniques as the prior studies of Ericson and Kurol,<sup>28</sup> attempted to identify canine impactions early with panoramic films. The study included 46 "early" mixed dentition subjects. Untreated controls selected for chronologic and dental age and also for sex were included. Sectors were established for canine positions relative to the adjacent permanent lateral

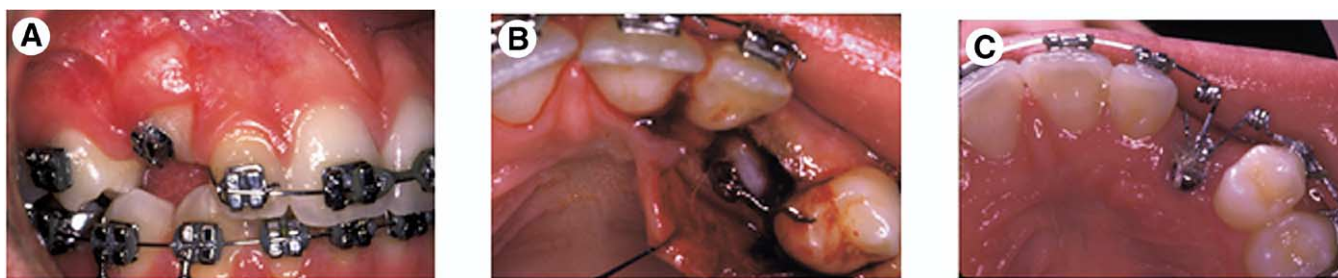


**Figure 6** (A) Panoramic radiograph showing inability of permanent canines to resorb primary canines. (B) Panoramic radiograph of the same patient 2 years later after extraction of the primary canines. Note that the permanent canines remained impacted.

incisor roots. They reported that 78% of the cases destined to become impacted were identified in sectors II, III, or IV. They also stated this demonstrates a sensitivity ratio of 0.78 and specificity of 0.96. [Figure 2](#) shows an 8-year-old child pre-

senting with spacing in the maxillary anterior region. The occlusal film showed mesial angulation of the maxillary right permanent canine compared with the left canine. The panoramic radiograph showed mesial angulation of the maxillary





**Figure 7** Surgical exposure of the impacted canine. (A) Apical repositioning flap was used to expose the maxillary right canine, which was found to be labially impacted. (B) A “closed eruption” technique was used to uncover the palatally impacted left canine. (C) Orthodontic traction was used to guide impacted canine into occlusion.

right permanent canine and distal crown angulation of the lateral incisors. No treatment was rendered at that time. Two years later, the panoramic radiograph showed that the maxillary right canine has crossed the lateral border of the lateral incisor (Fig 3). Extraction of the primary canine was performed. Two years later, the path of eruption of the maxillary canine was found to be improved and the periapical radiograph showed that the lateral incisor was small and peg shaped with a dilacerated root.

Computer tomography (CT) has become more widely available and is recognized as an important diagnostic tool for complex conditions in the oral region.<sup>30</sup> CT scan was found superior to plain film radiograph in the early detection of root resorption of the lateral maxillary incisor by the ectopically erupted permanent canine.<sup>31</sup> CT scan is beneficial for com-

prehensive evaluation and for treatment planning of impacted teeth, especially in the crowded field of the mixed dentition. However, radiation risk from a panoramic or intraoral radiograph is lower than from CT scans. Thus, the radiation risk should be weighed against the diagnosis and surgical benefits of precise preoperative management of the impacted canine. New computer software (Lumen IQ, Inc, Bellingham, WA) is now available to enhance plain film radiographs to be viewed as 3D images (see Fig 9D). Digital 3D panoramic and cephalometric imaging will soon be available at an affordable price so that orthodontists can diagnose impacted canines with accuracy.

## Treatment

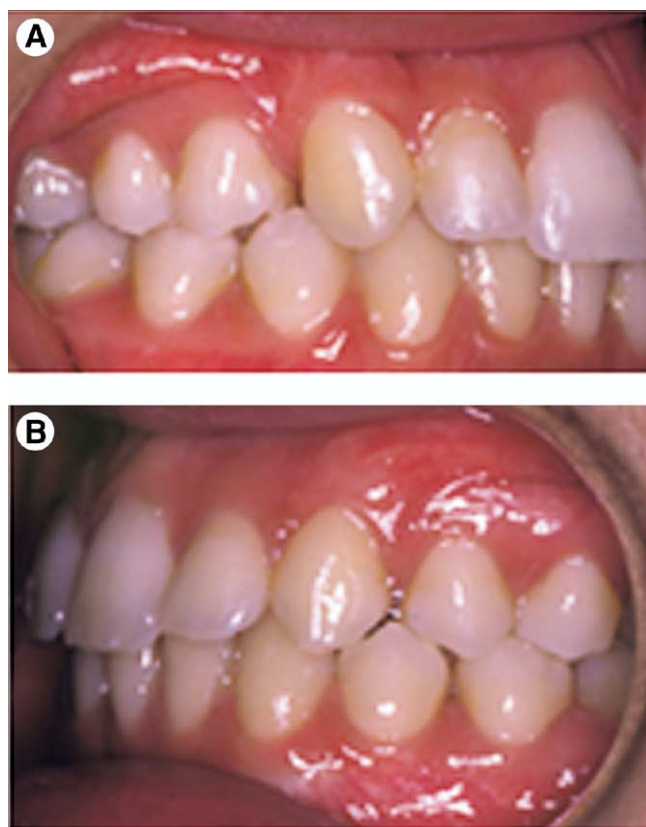
### Extraction of Primary Canines

It is recommended that orthodontists should monitor the eruption of permanent maxillary canines before age 10. If the eruption pattern of the permanent canines appears to be destined for impaction, most authors agree that the primary canine should be extracted.<sup>20,24,26,27,32,33</sup> This in fact has been shown to be effective in up to 91% when the permanent canine is located distal to the long axis of the lateral incisor, yet only 64% effective when the canine overlaps medially to the long axis midline of the lateral incisor.<sup>34</sup> This further emphasizes the need for routine examination, palpation, and radiographs beginning perhaps as early as 8 years of age followed by similar 6-month follow-up observations and procedures until the patient is 10 years of age. Figure 4 shows a 6-year-old child with abnormal angulation of the developing maxillary left canine. One year later, the progress panoramic radiograph showed no improvement in the path of eruption. Extraction of the primary canine was performed. Three years later, there was significant improvement in the path of eruption and the maxillary canine erupted into occlusion without further treatment.

### Uncovering of Impacted Canines

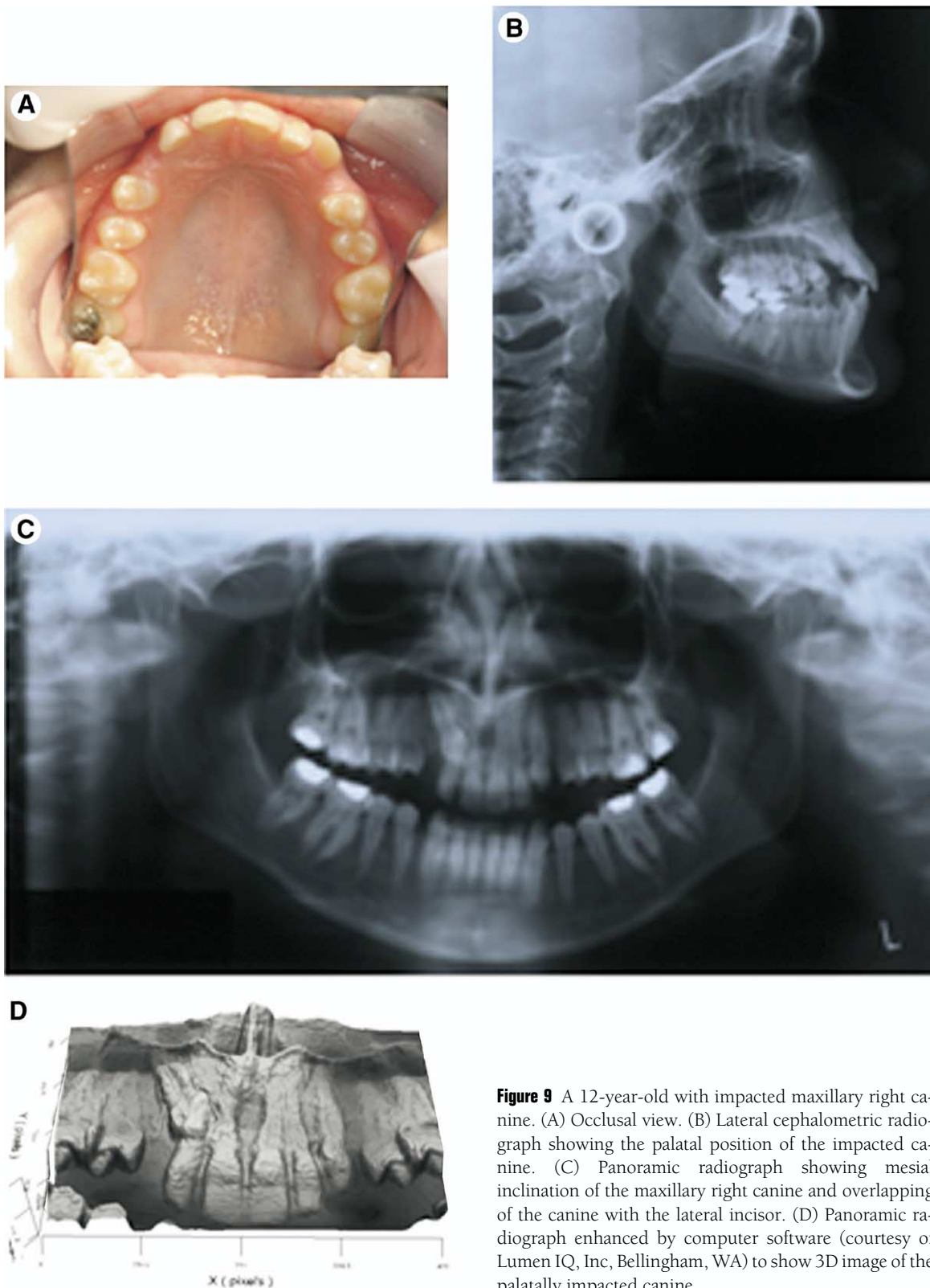
Surgical uncovering of impacted canines has been advocated for occlusal, functional, and esthetic reasons.<sup>35</sup> Timely uncovering of impacted canine can prevent formation of a cyst,<sup>35</sup> periodontal defects,<sup>37</sup> and resorption of the adjacent teeth.<sup>36</sup>

Treating unerupted canines can present problems of devi-



**Figure 8** Posttreatment result showing tissue response to surgically exposed canines. (A) Right lateral view. (B) Left lateral view.

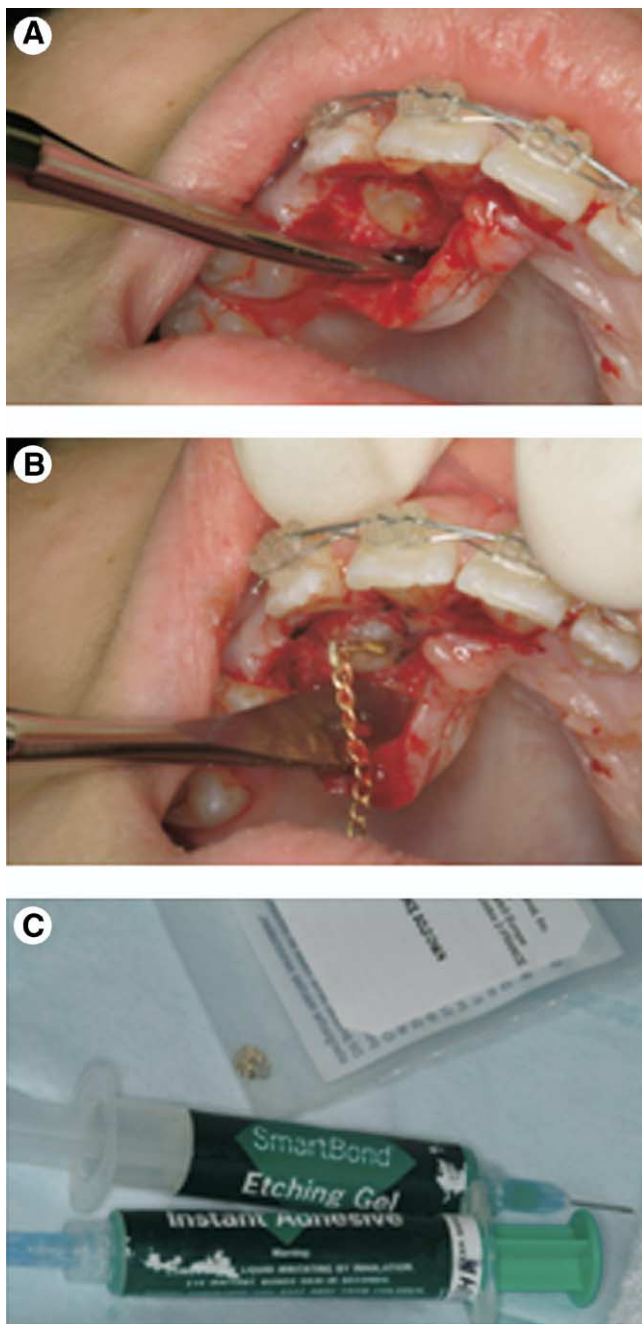




**Figure 9** A 12-year-old with impacted maxillary right canine. (A) Occlusal view. (B) Lateral cephalometric radiograph showing the palatal position of the impacted canine. (C) Panoramic radiograph showing mesial inclination of the maxillary right canine and overlapping of the canine with the lateral incisor. (D) Panoramic radiograph enhanced by computer software (courtesy of Lumen IQ, Inc, Bellingham, WA) to show 3D image of the palatally impacted canine.

talization, ankylosis, external root resorption, injury to adjacent teeth, and the need for reexposure. Additionally, marginal bone loss, gingival recession, and sensitivity problems can occur. These effects result in prolonged treatment time, esthetic deformities, and often the loss of teeth. Most of these problems can be prevented with proper management of peri-

odontal tissues and timing of care. The use of electrosurgical or laser techniques is discouraged for exposure of these teeth. These instruments are designed for removal of hard and soft tissues, which may, when contacting the tooth, lead to permanent damage of either type of tissue and/or devitalization of the tooth. Excision of tissues must be carefully performed



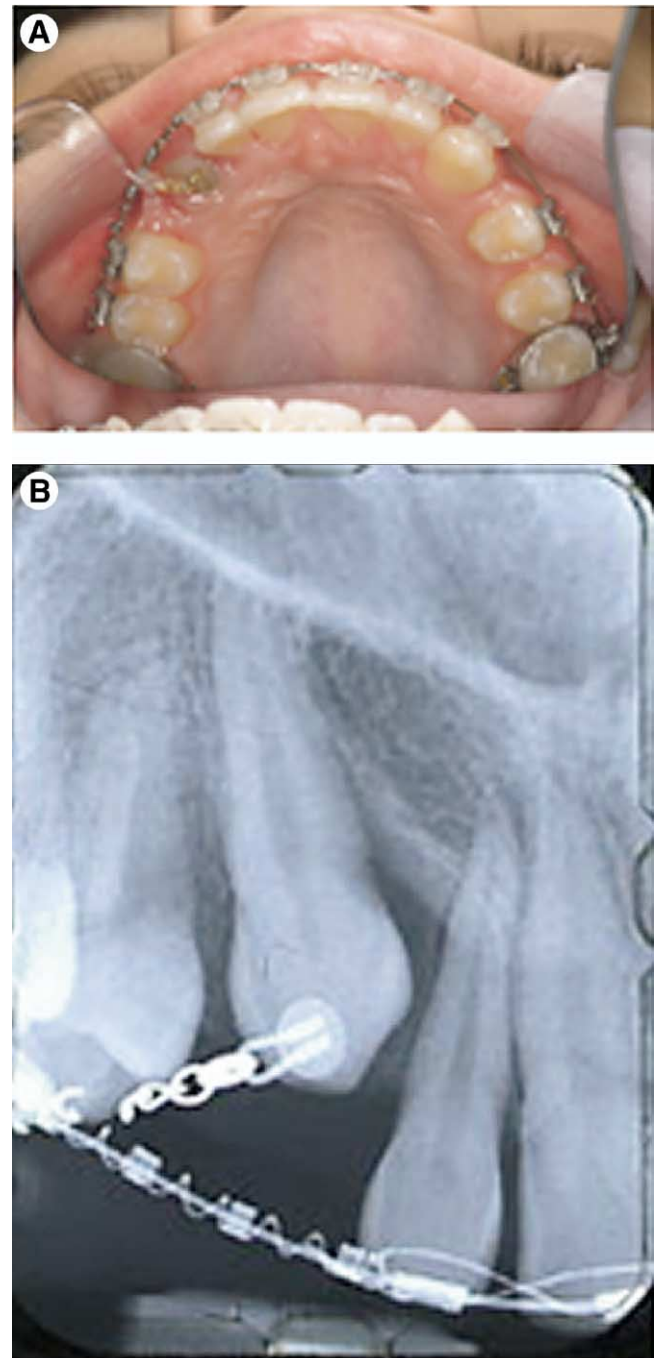
**Figure 10** (A) Surgical exposure of the impacted canine. (B) Bonding of eyelet and gold chain to the lingual surface of the impacted canine. (C) Etching gel and adhesive (SmartBond) used to bond the eyelet and gold chain.

even by experienced operators. When done incorrectly, the unerupted tooth may be left with inadequate keratinized tissue.

### Labial Impaction

There is conclusive evidence that an open eruption approach through nonkeratinized gingival should be avoided.<sup>34</sup> An apically repositioned flap or closed eruption through keratinized gingival tissue is recommended.<sup>33</sup> If the tissue is too thin to be dissected as a partial thickness graft, a free gingival graft can be performed initially to increase the thickness of kera-

tinized tissue. After approximately 30 to 60 days or complete healing of the grafted tissue, the tooth may be exposed, bonded, and have orthodontic traction implemented. **Figure 5** shows a 14-year-old patient with delayed eruption of the permanent teeth and bilateral impacted maxillary canines. The panoramic radiograph showed the inability of the permanent canine to resorb the primary canines (**Fig 6**). Surgical exposure of the impacted canines was performed. An apical repositional flap was used to expose the maxillary right canine, which was found to be labially impacted. A “closed



**Figure 11** (A) Periapical radiograph showing orthodontic traction to move the crown of the maxillary canine away from the root of the lateral incisor. (B) Occlusal view showing orthodontic traction to move impacted canine buccally into occlusion.

eruption" technique was used to uncover the maxillary left canine, which was found to be palatally impacted (Fig 7). Orthodontic traction was used to guide the impacted canines into occlusion (Fig 8).

## Palatal Impaction

Because the palate is entirely masticatory mucosa, grafts are not necessary. Two basic surgical techniques are widely used. In a "closed eruption" technique in which the crown is surgically exposed, an attachment is bonded during the exposure and the flap sutured back over the crown, leaving a twisted ligature wire or a gold chain passing through the mucosa to apply the orthodontic traction (Figs 9, 10, and 11). A direct bonding of the impacted canine at the time of surgery may cause soft tissue injury from the acid etching used in an open wound. Moreover, bleeding control to avoid blood and saliva contamination and maintain a dry field may be difficult for the successful bonding of an orthodontic attachment, especially when impaction is deep. We (the authors of the article) have success using the adhesive Smart-Bond to attach the gold eyelet and chain to the exposed tooth (Fig 10C). In addition, the eruption of the impacted tooth may be delayed as it must overcome the resistance of a dense and thick soft palatal tissue. In the "open window" eruption technique, a flap is raised and a minimal amount of bone is removed, enough to expose the tip of the impacted crown to be bonded. The flap is then returned and sutured with a small "window" cut into the flap of the palatal soft tissue, covering the embedded crown packed with surgical dressing for 1 week. The orthodontic attachment can be bonded at a later time after the removal of the pack. According to Becker and coworkers, bonding at that time is superior to its performance at a later date.<sup>38</sup> The use of an eyelet attachment has a lower failure rate than the use of a conventional bracket. Becker and coworkers also found that the palatal surface offers the poorest bonding surface and that pumicing the exposed tooth offers no advantage over immediate etching of the exposed enamel.<sup>38</sup>

Orthodontic traction on the impacted tooth should be applied with light forces (20 to 30 g). In most instances, a tipping movement is all that is necessary to move the crown toward the dental arch. Since the root tip of the impacted canine is usually in a good position, mechanics that will allow primarily controlled tipping of the clinical crown is recommended. An example will be the use of a "mouse trap" device to erupt the tooth vertically and buccally toward the dental arch (Fig 7C). However, if the impacted canine is situated palatal to the lateral incisor, an attempt should be made to first move the canine away from lateral incisor before moving the impacted tooth toward the dental arch (Fig 11A and B).

## Conclusions

1. Periodic examination starting at age 8, including intraoral palpation to check the space available for the unerupted permanent canine, the morphology and position of the adjacent teeth, the contours of the bone, the mobility of the teeth, and the radiographic assess-

ment to determine the position of the canine can help in diagnosing potentially impacted maxillary canine teeth.

2. Early extraction of the maxillary primary canine can facilitate the eruption of potentially impacted permanent canines.
3. Timely uncovering of impacted canines can prevent formation of cysts, periodontal defects, and resorption of the adjacent teeth.

## Acknowledgment

The authors would like to thank Dr. Ross Crist for his assistance in preparing the literature review for this manuscript.

## References

1. Regezi JA, Sciubba JJ: Oral Pathology Clinical-Pathologic Correlations. Philadelphia, PA, WB Saunders, 1989, p 469
2. Dachi SF, Howell FV: A survey of 3,874 routine full mouth radiographs: II. A study of impacted teeth. *Oral Surg Oral Med Oral Pathol* 14:1165-1169, 1961
3. Moyers RE: Handbook of Orthodontics. 4th ed. Chicago, IL, Year Book Medical Publishers, 1988
4. Thilander B, Myrberg N: The prevalence of malocclusion in Swedish school children. *Scand J Dent Res* 81:12-20, 1973
5. Rohrer A: Displaced and impacted canines. *Int J Orthod Dent Child* 15:1003-1020, 1929
6. Fournier A, Turcotte JY, Bernard C: Orthodontic considerations in the treatment of maxillary canines. *Am J Orthod* 81:236-239, 1982
7. Becker A, Smith P, Behar R: The incidence of anomalous maxillary lateral incisors in relation to palatally-displaced cuspids. *Angle Orthod* 51: 24-29, 1981
8. Hitchen AD: The impacted maxillary canine. *Br Dent J* 1001-14, 1956
9. Rayne J: The unerupted maxillary canine. *Dent Pract* 19194-204, 1969
10. Bishara SE: Impacted maxillary canines: a review. *Am J Orthod Dentofacial Orthop* 101: 159-171, 1992
11. Fearn J, Lee RT: Favorable spontaneous eruption of severely displaced maxillary canines with associated follicular disturbance. *Br J Orthod* 115:93-98, 1988
12. Jacoby H: The etiology of maxillary canine impactions. *Am J Orthod* 84:126-132, 1983
13. Miller BH: The influence of congenitally missing teeth on the eruption of the upper canine. (Transactions of the BSSO.) *Dent Pract* July 24:17-24, 1963
14. Becker A, Zilberman Y, Tsur B: Root length of lateral incisors adjacent to palatally displaced maxillary cuspids. *Angle Orthod* 54:218-225, 1984
15. Peck S, Peck L: The palatally displaced canine as a dental anomaly of genetic origin. *Angle Orthod* 1994:249-256
16. Van der Linden PGM: Transition of the Human Dentition. Monograph #13, Craniofacial Growth Series. Ann Arbor, MI, Center for Human Growth and Development, University of Michigan, pp 102-105, 1982
17. Nanda SK: The developmental basis of occlusion and malocclusion. Chicago, IL, Quintessence Publishing, 1983, pp 118-127
18. Brand RW, Isselhard DE: Anatomy of Orofacial Structures. 3rd ed. St. Louis, MO, CV Mosby, 1986
19. Hurme VO: Ranges of normalcy in the eruption of permanent teeth. *J Dent Child* 16:11-15, 1949
20. Leivesley WD: Minimizing the problem of impacted and ectopic canines. *J Dent Child* Sept-Oct:367-370, 1984
21. Power SM, Short MBE: An investigation into the response of palatally displaced canines to the removal of deciduous canines and an assessment of factors contributing to favourable eruption. *Br J Orthod* 20: 215-223, 1993
22. Moss JP: The unerupted canine. *Dent Pract* 22:6; 241-248, 1972
23. Langlais RP, Langland OF, Morris CR: Radiographic localization techniques. *Dent Radiol Photogr* 52:69-177, 1979



24. Bishara SE: Impacted maxillary canines: a review. *Am J Orthod Dentofacial Orthod* 101:159-171, 1992
25. Ericson S, Kuroi J: Radiographic assessment of maxillary canine eruption in children with clinical signs of eruption disturbances. *Eur J Orthod* 8:133-140, 1981
26. Williams BHJ: Diagnosis and prevention of maxillary cuspid impaction. *Angle Orthod* 51:1;30-40, 1981
27. Ngan P, Wolf T, Kassoy G: Early diagnosis and prevention of impaction of the maxillary canine. *J Dent Child Sept-Oct*:335-338, 1987
28. Ericson S, Kuroi J: Radiographic examination of ectopically erupting maxillary canines. *Am J Orthod Dentofac Orthop* 91:483-492, 1987
29. Lindauer SJ, Rubenstein LK, Hang WV, et al: Canine impaction identified early with panoramic radiographs. *J Am Dent Assoc* 123:91-97, 1992
30. Bodner L, Sarnat H, Bar-Ziv J, et al: Computed tomography in the management of impacted teeth in children. *J Dent Child Sept-Oct*:370-377, 1994
31. Ericson S, Kuroi J: CT diagnosis of ectopically erupting maxillary canines: a case report. *Eur J Orthod* 10:115-120, 1988
32. Ericson S, Kuroi J: Early treatment of palatally erupting maxillary canines by extraction of the primary canines. *Eur J Orthod* 10:283-295, 1988
33. Kuflinec MM, Stom D, Shapira Y: The impacted maxillary canine: I. Review of concepts. *J Dent Child Sept-Oct*:317-324, 1995
34. Vermette ME, Kokich VG, Kennedy DB: Uncovering labially impacted teeth: apically positioned flap and closed-eruption techniques. *Angle Orthod* 65:23-32, 1995
35. Kuflinec MM, Stom D, Shapiro Y: The impacted maxillary canine: II. Clinical approaches and solutions. *J Dent Child Sept-Oct*:325-334, 1995
36. Rimes RJ, Mitchell CNT, Willmot DR: Maxillary incisor root resorption in relation to the ectopic canine: a review of 26 patients. *Eur J Orthod* 19:75-84, 1997
37. Wise RJ: Periodontal diagnosis and management of the impacted maxillary cuspid. *Int J Period Restor Dent* 1:56-73, 1981
38. Becker A, Shpack N, Shteyer A: Attachment bonding to impacted teeth at the time of surgical exposure. *Eur J Orthod* 18:457-463, 1996