Volume II, Number 4
Case Studies in Orthodontics
An Accredited Continuing Education Program for Orthodontists
Sponsored by sonicare
Series Editor: Dr. Gregory J. King • Chair, Department of Orthodontics • University of Washington School of Dentistry

Treatment of a Class II Malocclusion With Herbst and Fixed Orthodontic Appliances: A Case Report

Jeffrey Gilmore, DDS, MS, D.Orth.
Private Practice
Marietta, OH

Peter Ngan, DMD, Cert Orth, D.Orth.
Professor and Chair
Department of Orthodontics
West Virginia University
School of Dentistry

Introduction

Approximately 30% of the malocclusions in the United States have a Class II relationship (McLain and Proffit, 1985). The prevalence of this type of malocclusion seems to be higher among people of Northern European descent (30–40%) and lower in African-Americans (18–20%).

A variety of protocols have been recommended for the treatment of a Class II malocclusion, including fixed appliances, extraction procedures, extra-oral traction and functional jaw orthopedic appliances. According to a study by McNamara (1981) on the components of a Class II malocclusion, over 60% of Class II cases have the mandible in a retruded position. Removable functional appliances have been used for the treatment of a skeletal Class II malocclusion with mandibular deficiency in an effort to induce mandibular growth by changing muscle function and the condylar-glenoid fossa relationship. In animal studies (Petrovic *et al.*, 1975; Hinton and McNamara, 1984), histologic examination following intermittent forward mandibular functioning shows proliferation of condylar cartilage after treatment. However, very few studies actually show an increase in mandibular length.

Dental Ankylosis

Dental ankylosis is the anatomical fusion of a tooth with alveolar bone, occurring at any time during the course of eruption. It may happen before emergence into the oral cavity, or during active eruption before contact is made with the opposing dentition (Messer and Cline, 1980). The primary second molar is the most frequently affected, followed by the deciduous first molar and the permanent first molar. Ankylosis of the permanent incisors is extremely rare; three

Editor's Note

Dear Reader:

This case offers an opportunity to discuss the management of ankylosed permanent teeth during orthodontic treatment. The first decision: Is the tooth in question really ankylosed? This case demonstrates that the only way to know for sure is to move it. History, radiographs and percussion can be helpful, but often the most conservative approach is to attempt movement. Once you decide that the tooth is ankylosed, luxation is often considered. As the authors correctly emphasize, there are reports of this approach being quite successful. These successes are difficult to understand from a biological perspective because orthodontic tooth movement requires many of the same mechanisms that would also permit re-ankylosis. Another option would be auto-transplantation. This requires an adult patient, an esthetic tooth and surgical management that does not jeopardize the tooth. Most often these teeth will re-ankylose, requiring endodontics and an acceptable recipient site.

We are indebted to the Optiva Corporation, makers of the Sonicare sonic toothbrush, for their support of the continuing education needs of orthodontists through their exclusive support of this program.

Gregory J. King, DMD, DMSc
Series Editor

theories have been offered to explain its etiology: 1) the *genetic theory* (Bosker *et al.*, 1978) showing a strong familial tendency in patients with this problem; 2) the *trauma theory* (Henderson, 1979) based on a previous traumatic incident that caused injury to the bone or periodontal ligament; and 3) the *theory of local disturbance of metabolism* (Biederman, 1956).

The diagnosis of ankylosis is usually based on three clinical signs. There may be a submerged or depressed appearance in relation to the adjoining teeth. Radiographically, the periodontal membrane in some areas may be obliterated with an apparent blending of the root with the adjacent bone. Percussion of the affected teeth reveals a solid, clear sound as if they were a part of the bone which houses them rather than the muffled and dull cushioned sound of normal teeth.

The treatment of dental ankylosis includes attempted orthodontic movement, repeated luxation to free up the areas of bony union and surgical repositioning (Vanarsdall, 1994).

Herbst Appliance

The Herbst distinguishes itself from other functionals by being a truly fixed appliance. The telescoping mechanism encourages forward repositioning of the lower jaw as the patient closes into occlusion. The original design of the appliance utilizes bands on the first premolars and molars (Pancherz, 1979). Howe and McNamara (1983) introduced the bonded Herbst which eventually evolved into the acrylic splint Herbst appliance. The effects of the Herbst appliance include an increase in mandibular length, distalization of the maxillary buccal segment and proclination of mandibular incisors. Woodside *et al.* (1987) reported on the effect of fixed functional appliances on glenoid fossa remodeling. Apparently, treatment with the Herbst appliance could be effective in patients of any age.

This paper presents a case report of an adolescent patient presenting with a Class II division 1 malocclusion and an ankylosed permanent central incisor. The diagnosis, treatment and management of this case will be discussed.

Case Presentation

The patient, a healthy, cooperative 14-year, 4-month-old Caucasian male, presented to the West Virginia University Orthodontic Clinic as a referral from his general dentist. His past medical and dental history were significant, including a heart murmur that required prophylactic antibiotic coverage prior to invasive dental procedures. The maxillary right central incisor had been avulsed two years ago in a bicycle accident. This tooth was re-implanted, stabilized and endodontically treated.

Diagnostic Summary

Facial photographic analysis from the frontal view (Figure 1a) revealed a mesofacial type. His soft tissue chin point was relatively centered with the facial midline. The vertical thirds of the face appeared to be balanced. Lip strain was

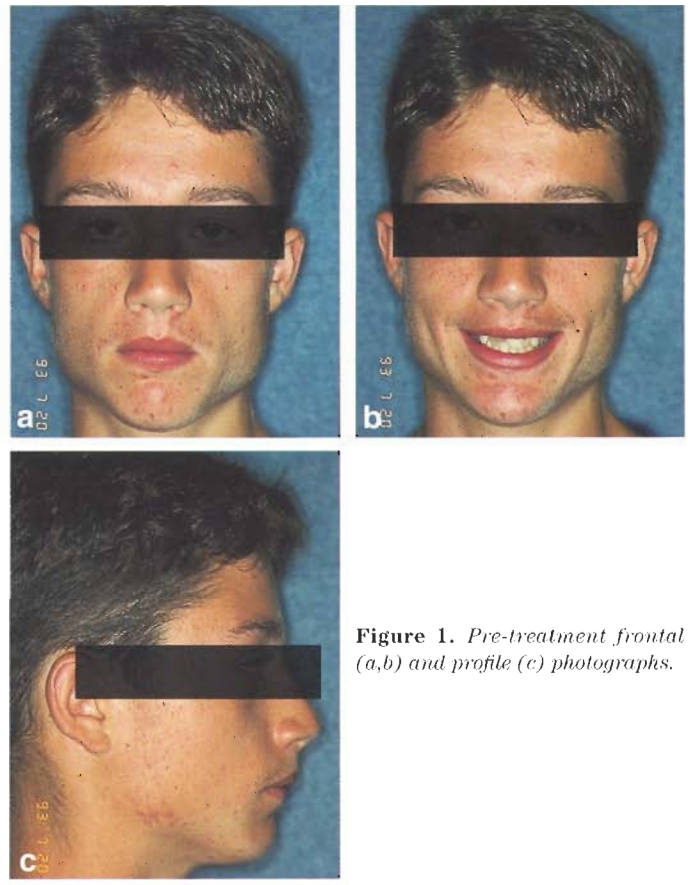

Figure 1. *Pre-treatment frontal (a,b) and profile (c) photographs.*

noted upon lip closure. The patient had a pleasing smile with no gingival display and the dental midlines were coincident with the facial midline (Figure 1b). In the profile photograph (Figure 1c), the patient exhibited a retrognathic convex facial pattern with an obtuse nasolabial angle.

Upon intraoral examination (Figure 2), the patient's oral hygiene was assessed to be fair with areas of marginal gingivitis. The maxillary right central incisor was darkened and had a chipped incisal edge. The tooth appeared to be superiorly positioned relative to its neighboring teeth, indicating possible ankylosis. The TMJ findings were within normal limits, with no history of TMD signs or symptoms. A functional examination revealed a deviation from centric relation to centric occlusion of less than 1 mm. The patient presented with an Angle Class II division 1 malocclusion with 6 mm overjet and 60% overbite. The maxillary arch form was narrow and tapered, with 5 mm of crowding and a high palatal vault. The mandibular arch form was also narrow and tapered with 4 mm of crowding. The curve of Spee was moderately deep.

The panoramic and periapical radiographs of the maxillary right central incisor (Figure 3) showed a completed root canal with healthy surrounding bone. However, the periodontal ligament space surrounding the root was not evident. The vertical tooth position and alveolar bone height were higher than the neighboring teeth. Clinical percussion of the tooth revealed a loud, solid sound that was distinctly different from the adjacent teeth. Analysis of the hand-wrist radiograph revealed the presence of a fully

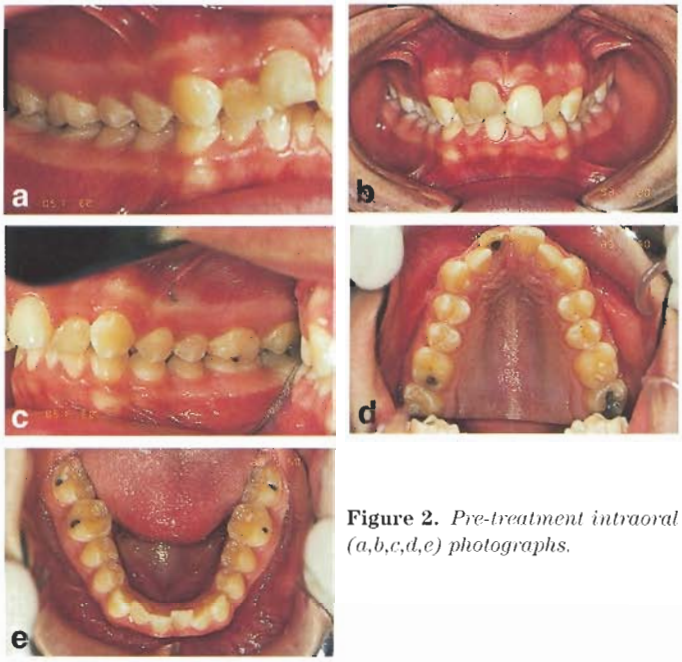

Figure 2. *Pre-treatment intraoral (a,b,c,d,e) photographs.*

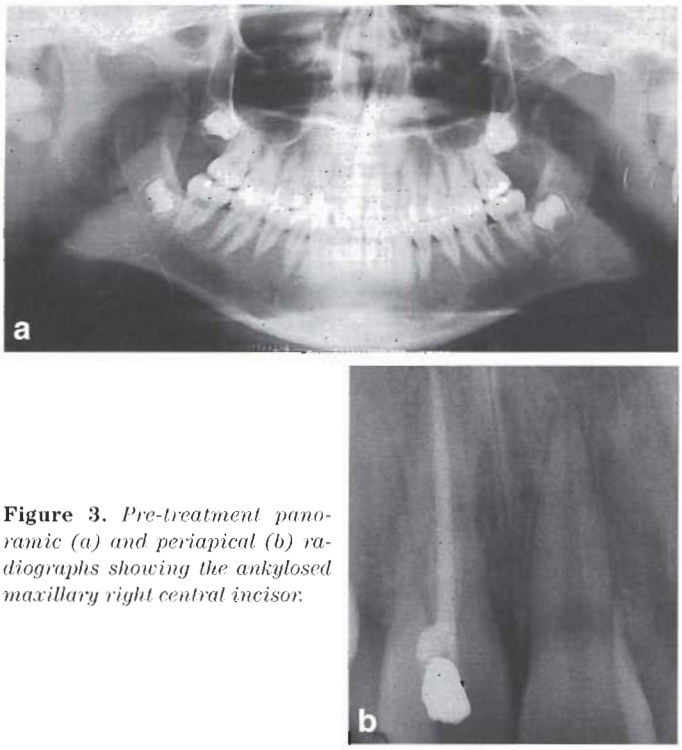

Figure 3. *Pre-treatment panoramic (a) and periapical (b) radiographs showing the ankylosed maxillary right central incisor.*

calcified sesamoid bone, capped MP3 (third middle phalanx) and fused PP2 (second proximal phalanx). According to the Atlas of Gruelich and Pyle, the patient had passed the maximum pubertal growth spurt with a skeletal age of 16. Analysis of the lateral cephalometric radiograph showed a Class II skeletal and dental relationship with a hypodivergent growth pattern. The maxilla was well-positioned anteroposteriorly (SNA = 82°, N-perp/A point = +1 mm), but the mandible was retrusive (SNB = 74°, N-perp/pog = –6 mm). A significant apical base discrepancy was noted (ANB = 8°, Wits = 7 mm) with a normal lower anterior to total facial height ratio (ANS-Me/N-Me = 55%).

Challenges

- Retrusive mandible with excess facial convexity;
- Constricted maxilla when the mandible was advanced to a Class I relationship;
- Bilateral Class II buccal segments with a 6 mm overjet and 60% overbite;
- Crowding in the maxillary and mandibular arches; and
- Ankylosis of the maxillary right central incisor.

Treatment Alternatives

Alternative 1

One alternative was to place a functional appliance, such as a Herbst appliance, to normalize the maxillo-mandibular relationship. An expansion appliance could be used in conjunction with the functional appliance to correct the transverse discrepancy. Luxation of the ankylosed maxillary incisor would be necessary prior to leveling with the adjacent teeth. If treatment of the ankylosis was not successful, extraction of the ankylosed tooth would be necessary, followed by prosthetic replacement. The orthopedic phase of treatment would be followed by comprehensive, non-extraction treatment with a fixed appliance to obtain an ideal molar relationship, overjet and overbite.

Alternative 2

If the mid-palatal suture failed to separate, another alternative for treating this malocclusion would be surgically assisted rapid maxillary expansion. If the functional appliance failed to normalize the maxillo-mandibular relationship, orthognathic surgery to advance the mandible, in conjunction with orthodontic treatment would be a consideration. This alternative treatment addresses all the challenges, but has the disadvantage of the risk and the cost of surgery.

Alternative 3

If the remaining growth was not favorable and the patient/family declined to pursue any form of orthognathic surgery, another alternative treatment to reduce overjet would be comprehensive orthodontic treatment with extraction of the maxillary first premolars. However, this would be a compromised situation with dental compensation for the skeletal Class II discrepancy. In addition, this treatment option would not address the profile concerns.

Treatment

All three treatment options were presented to the patient and the pros and cons of each were thoroughly explained to the family. The parents were supportive of the first alternative and the patient was excited to begin treatment.

An acrylic splint Herbst appliance with an expansion screw was used to correct the anteroposterior and transverse discrepancies. The maxillary component was bonded to the maxillary premolars and molars. The patient's mother was instructed to turn the expansion screw two times (0.5 mm) per day until a total of 28 turns (7 mm) was achieved.

The removable mandibular component of the Herbst appliance was then inserted with an initial advancement of 4–5 mm. Sleeves of tubing were added over the mandibular plunger (1 mm/month) until an edge-to-edge incisal relationship was obtained. The Herbst appliance was removed after 8 months of treatment, and orthodontic brackets and bands were placed immediately. The patient was then referred to the oral surgery department for luxation of the ankylosed maxillary central incisor. No significant movement was observed over the subsequent 4 months. The decision was made to remove the ankylosed tooth and replace it with an acrylic denture tooth. The mandible settled to an ideal Class I relationship. A .019" × .025" closing loop was used to close maxillary anterior space, and maximum posterior intercuspation was achieved using up and down finishing elastics.

Treatment Results

The active treatment time was 28 months; 8 months of Herbst appliance treatment and 20 months of fixed appliance treatment. The computerized tomograms taken at the end of the Herbst treatment show both the left and right condyles were centered in the fossa (Figure 4). On panoramic evaluation (Figure 5) no apical blunting was evident and root paralleling was acceptable. The third molars appeared to be developing normally. Superimposition of the pre- and post-treatment cephalometric radiographs (Figure 6) showed that the patient exhibited favorable forward mandibular growth during the remaining growth period. The profile was improved with a better maxillo-mandibular relationship. The position of the maxilla (A point) did not change. Maxillary molars moved forward 1–2 mm; maxillary incisors were slightly retroclined (1 mm) and mandibular incisors were proclined by 2 mm.

Post-treatment facial photographs (Figure 7) showed a well-balanced profile and a pleasing smile. Post-treatment

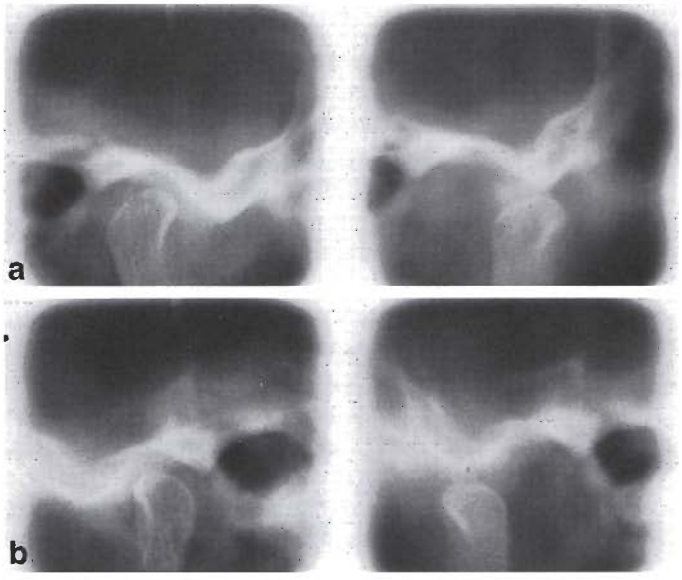

Figure 4. *Computerized tomograms of the right (a) and left (b) condyles before and after orthopedic treatment. Note the concentricity of the condyles post-treatment (left image in both figures).*

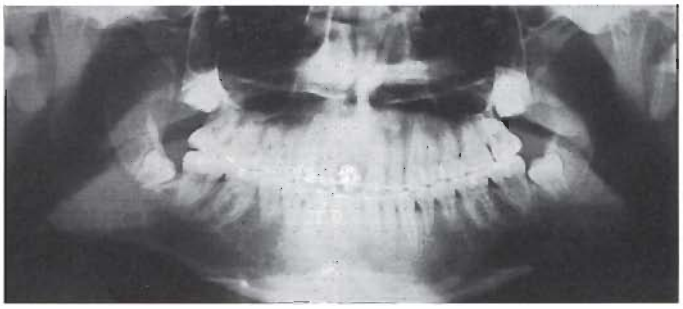

Figure 5. *Post-treatment panoramic radiograph showing good root parallelism.*

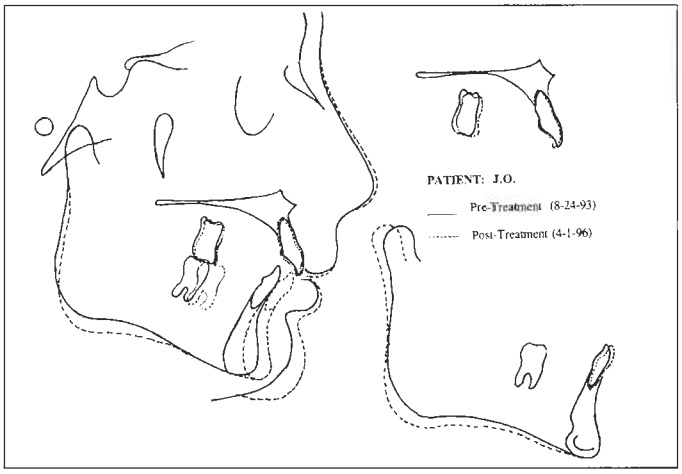

Figure 6. *Overall maxillary and mandibular superimpositions.*

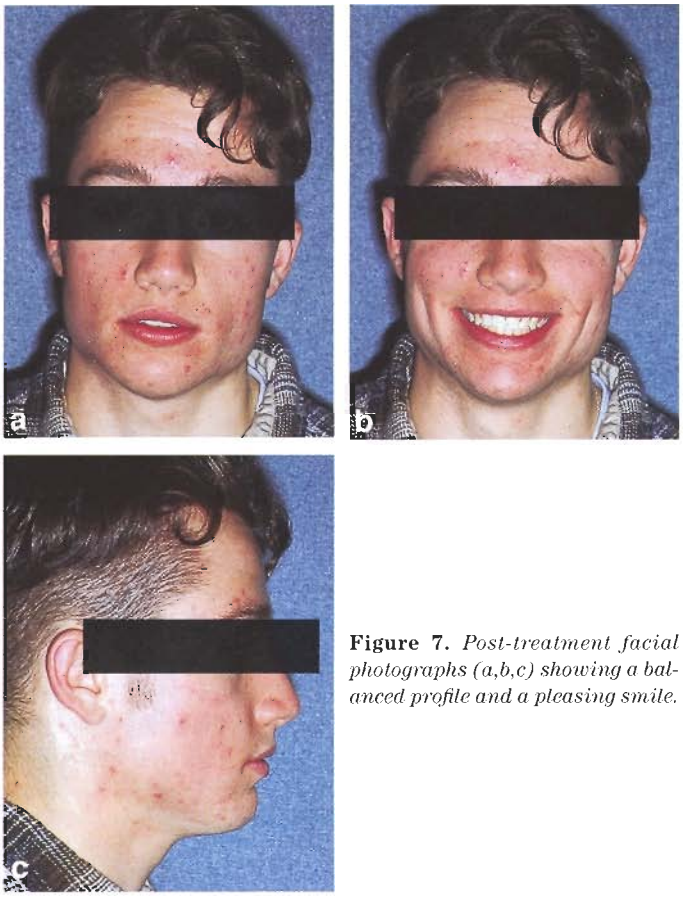

Figure 7. *Post-treatment facial photographs (a,b,c) showing a balanced profile and a pleasing smile.*

intraoral photographs (Figure 8) showed a bilateral Class I occlusion with ideal interdigitation of the posterior teeth. On lateral excursions, canine disocclusion was achieved with no balancing interferences. The overjet was reduced from 6 mm to 1 mm, and the overbite was reduced from 60% to 10%. The TMJ remained asymptomatic with a normal range of mandibular motion.

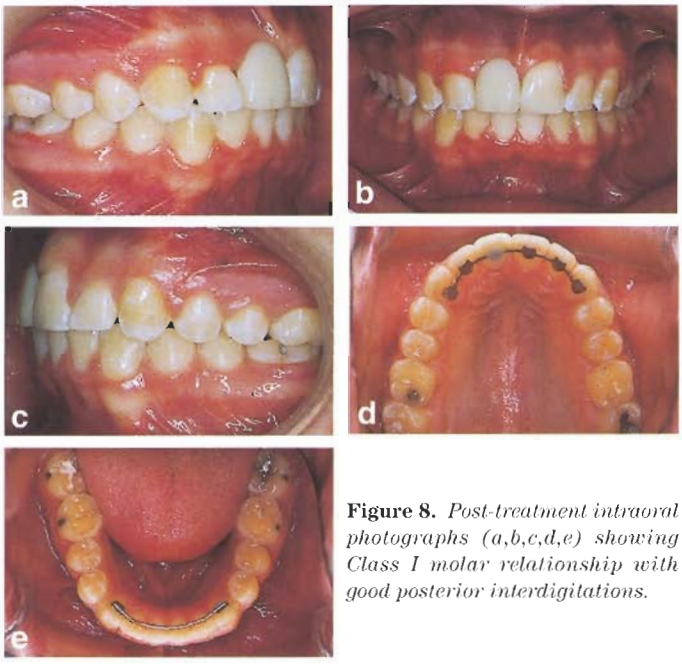

Figure 8. *Post-treatment intraoral photographs (a,b,c,d,e) showing Class I molar relationship with good posterior interdigitations.*

Retention

Maxillary and mandibular lingually bonded canine-to-canine retainers were placed at the completion of active treatment. A pontic was added to the maxillary retainer to replace the missing maxillary right central incisor. This modification produced a very favorable esthetic result that worked well for the patient. Ultimately, the patient will be a candidate for a dental implant or fixed prosthesis to replace the missing tooth. The development and eruption of the third molars would be monitored throughout the retention period.

Discussion

The success of treatment in this case can be attributed to the ability to elicit skeletal expansion and favorable sagittal and vertical growth of the condyle during the pubertal growth period. Treatment with the Herbst functional appliance was reported to be effective in mixed dentition (Wieslander, 1984), during pubertal growth (Pancherz and Hagg, 1985), as well as in late adolescence (Bakke and Paulsen, 1989).

In the present subject, a Hyrax expansion screw (Palex™ Expansion Screw, Great Lakes Orthodontic Products, Tonawanda, NY) was incorporated in the acrylic splint Herbst appliance for transverse expansion. Every one millimeter of expansion provides 0.7 mm increase in arch perimeter (Germane *et al.*, 1991) which can be utilized for the correction of crowding in the maxillary arch without excessive proclination of the maxillary incisors.

A combination of forward mandibular growth, proclination of mandibular incisors, and slight retroclination of maxillary incisors contributed to the 6 mm overjet correction. According to a study by Pancherz and Hansen on Herbst patients (1988), 48% of the overjet correction was contributed by forward mandibular growth, 8% by retrusion of the maxilla, 35% by proclination of the mandibular incisors and 9% by retroclination of the maxillary incisors. In the present case, condylar growth was favorable. Using the method described by Creekmore (1967), the effective condylar growth of this patient during the 2.5 years of treatment was 5 mm (3 mm horizontal and 3 mm vertical growth). In animal experiments, the Herbst appliance has been shown to increase condylar length as well as remodeling and relocation of the glenoid fossa (Woodside *et al.*, 1987). The position of the condyles was checked with sagittal tomography to be centered after treatment. In a study by Ruf and Pancherz (1998) on the condyle-fossa relationship after Herbst treatment, the condyles of the patients prior to treatment were found to be anteriorly positioned rather than concentrically. Post-treatment, the average condylar position was insignificantly more anterior than pre-treatment.

Proclination of mandibular incisors is commonly seen during Herbst treatment due to mandibular anchorage loss (Pancherz, 1979). This tooth movement, however, can be prevented since there is a strong tendency for the incisors to return to their pre-treatment position after treatment. Pancherz and Hansen (1988) showed that about 80% of the incisor movement recovered after treatment.

An attempt was made in this case to erupt the ankylosed permanent incisor after luxation. According to the literature, luxation should be attempted for ankylosed teeth that do not have crestal external root resorption or crestal ankylosis that can be seen upon tissue reflection. Once these teeth are freed by luxation, an immediate continuous force can be used to position the tooth orthodontically into the arch (Vanarsdall, 1994). In general, multi-rooted molars or canines with dilacerated roots have a poorer prognosis for movement after luxation than normally shaped, single-rooted teeth. In the present case, luxation was attempted without success. Extraction of the ankylosed tooth revealed extensive replacement resorption that was not evidenced on the pretreatment radiograph (Figure 9).

Figure 9. *Extracted maxillary right central incisor showing extensive root resorption that was not evidenced on the pre-treatment radiograph.*

A denture tooth was incorporated in the bonded lingual retainer as a temporary restoration for the edentulous space. Normally, an .022" multi-stranded wire is recommended for fixed maxillary retainers (Zachrisson, 1997). In this case, a stainless steel wire with prefabricated pads was used to incorporate the denture tooth on the fixed retainer. Prosthetic replacement of the extracted tooth is eventually needed when successive cephalometric radiographs show that growth is completed.

Acknowledgment: This case was treated by Dr. Annie Hu.

References

1. Bakke M, Paulsen HU: Herbst treatment in late adolescence: Clinical, electromyographic, kinesiographic, and radiographic analysis of one case. *Eur J Orthod* 11:397–407, 1989.
2. Biederman W: The incidence and etiology of tooth ankylosis. *Am J Orthod* 42:921–926, 1956.
3. Bosker H, Ten Kate LP, Nijenhuis LE: Familial reinclusion of permanent molars. *Clin Genet* 13:314–320, 1978.
4. Creekmore TC: Inhibition or stimulation of the vertical growth of the facial complex, its significance to treatment. *Angle Orthodontist* 37: 285–297, 1967.
5. Germane N, Lindauer SJ, Rubenstein LK, *et al:* Increase in arch perimeter due to orthodontic expansion. *Am J Orthod Dentofac Orthop* 100: 421–427, 1991.
6. Henderson HZ: Ankylosis of primary molars: A clinical, radiographic, and histologic study. *J Dent Child* Mar–Apr:117–122, 1979.
7. Hinton RJ, McNamara JA: Temporal bone adaptations in response to protrusive function in juvenile and young adult rhesus monkeys (Macaca mulatta). *Eur J Orthod* 6:155–174, 1984.
8. Howe RP, McNamara JA, Jr.: Clinical management of the Herbst appliance. *J Clin Orthod* 17:456–463, 1983.
9. McLain JB, Proffit WR: Oral health status in the United States: Prevalence of malocclusion. *J Dent Educ* 49:386–396, 1985.
10. McNamara JA , Jr.: Components of Class II malocclusion in children 8-10 years of age. *Angle Orthod* 51:177–202, 1981.
11. Messer LB, Cline JT: Ankylosed primary molars: Results and treatment recommendations from an eight-year study. *Pediatric Dent* 2:37–47, 1980.
12. Pancherz H: Treatment of Class II malocclusion by jumping the bite with the Herbst appliance: A cephalometric investigation. *Am J Orthod* 76:423–442, 1979.
13. Pancherz H: The mechanism of Class II correction in Herbst appliance treatment: A cephalometric investigation. *Am J Orthod* 83:104–113, 1982.
14. Pancherz H, Hagg U: Dentofacial orthopedics in relation to somatic maturation. *Am J Orthod* 88:273-287, 1985.
15. Pancherz H, Hansen K: Mandibular anchorage in Herbst treatment. *Eur J Orthod* 10:149–164, 1988.
16. Petrovic AG, Stutzmann JJ, Oudet CL: Control processes in the postnatal growth of the condylar cartilage of the mandible. In: McNamara JA, ed. *Determinants of mandibular form and growth*, 1975.
17. Monograph 4, Center for Human Growth and Development, University of Michigan, 1975.
18. Ruf S, Pancherz H: Temporomandibular joint growth adaptation in Herbst treatment: A prospective magnetic resonance imaging and cephalometric roentgenographic study. *Eur J Orthod* 20:375–388, 1998.
19. Vanarsdall RL: Periodontal/orthodontic interrelationships. In Vanarsdall RL, Graber TM, ed. *Orthodontics: Current Principles and Techniques*, 2nd edition, CV Mosby, St. Louis, pp. 741–748, 1994.
20. Wieslander L: Intensive treatment of severe Class II malocclusions with a headgear-Herbst appliance in the early mixed dentition. *Am J Orthod* 86:1-13, 1984.
21. Woodside DG, Metaxas A, Altuna G: The influence of functional appliance therapy on glenoid fossa remodeling. *Am J Orthod Dentofac Orthop* 92:181–198, 1987.
22. Zachrisson BU: Important aspects of long-term stability. *J Clin Orthod* 31:562-583, 1997.

C.E. Quiz

1. The incidence of Class II malocclusion in the United States is approximately
   a. 5%. c. 30%.
   b. 10%. d. 50%.

2. According to the study by McNamara, how many percent of Class II cases have a retruded mandible?
   a. 20% c. 60%
   b. 40% d. 80%

3. The skeletal and dental effects of a Herbst appliance include
   a. distalization of maxillary buccal segment only.
   b. increase in mandibular length only.
   c. proclination of mandibular incisors only.
   d. All of the above

4. The most frequently affected teeth with dental ankylosis are
   a. permanent maxillary incisors.
   b. primary second molars.
   c. primary first molars.
   d. permanent mandibular first molar.

5. The etiology of dental ankylosis can be explained by the following theories ***except***
   a. the genetic theory.
   b. the functional matrix theory.
   c. the trauma theory.
   d. the disturbance of local metabolism theory.

6. Diagnosis of dental ankylosis is usually performed by
   a. percussion only. c. observation only.
   b. radiographs only. d. All of the above

7. According to Pancherz and Hansen, mandibular growth contributed how many percent to the overjet correction in Herbst treatment?
   a. 28% c. 48%
   b. 38% d. 58%

8. According to Germane, 1 mm of maxillary expansion provided how many millimeters of arch perimeter?
   a. 0.5 mm c. 1.0 mm
   b. 0.7 mm d. 1.5 mm

9. According to the study by Ruf and Pancherz, the position of condyle in the fossa is usually
   a. concentric.
   b. slightly anterior to the center of the fossa.
   c. slightly posterior to the center of the fossa.
   d. None of the above

Reprinted from Pediatric Dentistry, March/April 1994.

REVIEW ARTICLE

Diagnosis and treatment planning for unerupted premolars

James Burch, DDS, MS Peter Ngan, DMD Al Hackman, DMD, MS

Abstract

Premolars rank third in frequency after third molars and maxillary canines in impacted or unerupted teeth. Failure to detect and analyze the problem may lead to unnecessary space loss, crowding, or collapse of the dental arch. A diagnostic scheme is presented to facilitate diagnosing and treating unerupted premolars. Important observations include:

- *Diagnosing congenitally missing permanent teeth*
- *Whether the condition is generalized or localized*
- *Whether the succedaneous tooth has a viable form, eruptive potential, and viable orientation*
- *Whether the delayed eruption is due to over-retained primary molars such as ankylosis and incomplete root resorption*
- *The amount of space available for the succedaneous tooth to erupt*
- *The presence of overlying soft tissue or bone.*

Space management and proper management of primary molars will frequently facilitate uneventful eruption of premolars. Orthodontic guidance of eruption is rarely indicated if problems can be detected early and managed properly. Four case reports elucidate the recommended treatment methods for these commonly occurring unerupted premolars. (Pediatr Dent 16: 89–95, 1994)

Introduction

One of the first steps in examining a pediatric dental patient with a mixed dentition is to determine the presence or absence of unerupted permanent teeth. Impacted or unerupted premolars rank third in frequency after third molars and maxillary canines.[1] Most of the literature focuses on the sequelae of the submergence, ankylosis, or early loss of the primary molars.[2–11] Few articles report the developmental course of unerupted premolars, with or without early interventions.

Etiological factors associated with unerupted premolars may include arch length deficiency, mechanical blockage, ectopic positioning, malformed teeth, ankylosis of the premolar, over-retention of primary teeth or ankylosed primary teeth, trauma, and systemic diseases.[12–14]

Ankylosis of primary teeth

The presence of ankylosed primary molar teeth may complicate eruption and development of the succedaneous permanent dentition. Typically, exfoliation of affected teeth is delayed[15] with subsequent complications such as:

- Deflected eruption paths for adjacent or opposing teeth[16]
- Impaction of succedaneous premolars[16, 17]
- Localized or generalized loss of needed arch length[15]
- Tipping of adjacent teeth over the ankylosed primary molar or supraeruption of opposing teeth.[15, 17–18]

These sequelae usually cause malocclusion.

Conservative approaches in treating ankylosed primary molars have been advocated after longitudinal study of such cases.[4–6] One study found that extracting ankylosed primary molars resulted in a gradual space loss in 14 of the 15 children.[5] Three approaches were recommended: observation, extraction, and restoration to occlusion. According to Messer and Cline,[4] the treatment recommendations should be based on the molar type, clinical pattern, and the severity of infraocclusion. For example, ankylosed mandibular second primary molars tend to become more severely infraoccluded as compared with mandibular first molars over time. Mesial tipping of the adjacent first permanent molar over the occlusal surface of the ankylosed tooth may occur, causing loss of arch length. The primary molar should be extracted if the tooth becomes moderately infraoccluded and/or mesial tipping of the mandibular first permanent molar is imminent. On the other hand, restoring solitary ankylosed primary mandibular molars showing only slight infraocclusion with restorations or stainless steel crowns to restore occlusion appears to be a useful interim treatment during the mixed dentition period. When the primary molar is ankylosed and the permanent premolar is congenitally absent, early orthodontic and prosthodontic consultations should be sought concerning long-term treatment of the dentition. A recent case report demonstrated an ectopically impacted premolar with radiolucent evidence of a defect in the crown.[19] Treating this problem may require immediate surgical exposure and restoration.

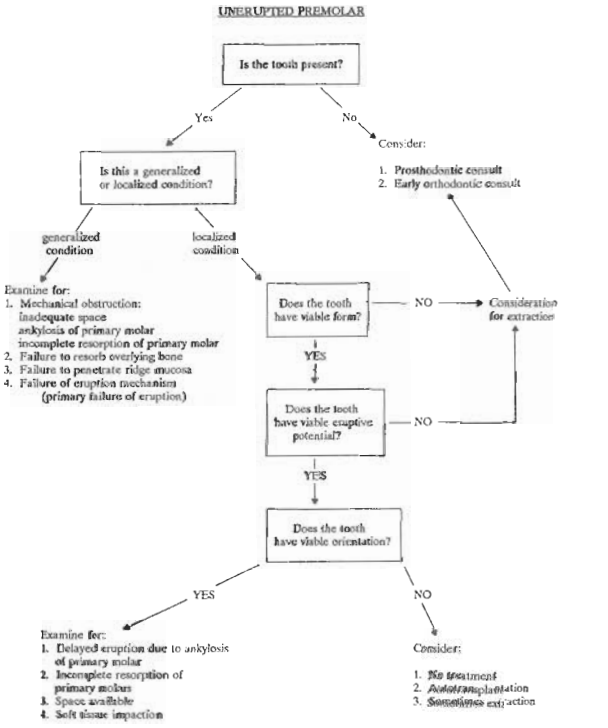

Fig 1. Diagnostic and treatment scheme for unerupted premolars.

Unerupted premolars

Unerupted teeth can be treated by either extraction or exteriorization of the crown of the impeded permanent tooth.[13] Three techniques of exteriorization include surgical exposure, repositioning, and orthodontic traction.

Surgical exposure is indicated if the tooth is in a normal eruptive position but retarded in its eruption after development of 3/4 of its root length. The procedure involves removing overlying bone and soft tissue and exposing the full occlusal surface of the impacted tooth. The impacted tooth is then allowed to erupt unaided by maintaining a patent channel from the crown to the oral cavity along the normal eruptive path. Various techniques have been used to ensure this patency including cementing a celluloid crown[20] or packing gutta percha material, zinc oxide eugenol,[21] or a surgical pack.[22]

Surgical repositioning or autotransplantation may be indicated if a tooth is in an abnormal axial inclination or, if once exposed, it does not erupt.[23, 24] The surgical technique was refined by Northway,[25] and various articles in the literature reported a high success rate of autotransplantation.[26, 27] Long-term studies of autotransplanted premolars by Andreasen[28, 29] demonstrated successful periodontal healing and continued root growth of the premolar, depending on the amount of damage to Hertwig's epithelial root sheath.

Finally, orthodontic traction may be used to guide eruption of the malpositioned and unerupted tooth with direct bonded attachments,[30] and applying a guidance force. Complications of orthodontic traction have been reported.[13] Reparative dentin has formed with varying degrees of pulpal obliteration, and dwarfed roots have formed making the tooth unresponsive to vitalometer stimulation.[13]

Diagnosis and treatment scheme for unerupted premolars

A number of critical observations help select the proper treatment approach for a specific patient. These include:

- Diagnosing missing succedaneous teeth
- Whether the condition is generalized or localized
- Whether the succedaneous teeth have viable form, eruptive potential, and viable orientation
- Whether the delayed eruption is related to overretained primary molars such as ankylosis and incomplete root resorption
- The amount of space available
- The presence of overlying soft tissue or bone.

The objectives of this paper are to direct the clinician through a diagnostic sequence of recognition and decision making in planning treatment for an unerupted premolar. Four case reports elucidate some recommended treatment methods for commonly occurring unerupted premolar conditions.

Fig 1 shows a diagnostic scheme to determine the problems and develop a treatment plan for the unerupting premolar. The first question is whether all the succedaneous teeth are present. The answer usually comes from routine clinical examination with a good dental history and appropriate radiographs such as panoramic, bite-wing, or periapical views. An unerupted premolar is usually detected from a routine bite-wing radiograph while its absence generally is confirmed by a routine panoramic radiograph. If present, its position is determined by comparing it with corresponding premolars in other quadrants. If the succedaneous premolars were missing in one or more quadrants, early orthodontic and prosthodontic consultations should be sought to determine the long-term treatment.

The second question is whether the condition is generalized or localized. If it is generalized, consider mechanical interferences with the eruptive process, such as an ankylosed primary molar, a supernumerary tooth, unresorbed root of a primary molar, or lack of available space. The usual mode of treatment will be to remove the mechanical obstruction, regain lost space, and observe the unerupted tooth over the next few months. Other possible problems are failure of overlying bone to resorb properly or failure of the tooth to penetrate the masticatory ridge mucosa. These situations require surgical exposure. Teeth may erupt independently, or

orthodontic treatment may be required to move the involved teeth into position. If the involved teeth fail to respond to direct orthodontic force, such as that provided by vertical elastics, the possibility of primary failure of eruption should be considered. This is a failure of the eruption mechanism, probably related to a periodontal ligament defect.[31] The treatment of choice would be surgical repositioning, possibly with autotransplantation[28, 29] or bone grafting.[31]

If the problem is localized, the next question is whether the tooth has a viable form. Teeth that are not viable should be considered for extraction with orthodontic and prosthodontic consultations regarding future space management and prosthetic replacement. On the other hand, teeth that are viable should be evaluated for their eruptive potential. Teeth with poor root morphology or ankylosis do not have good eruptive potential. If teeth cannot be brought into function with orthodontic therapy, a restoration may be indicated to establish occlusal contact. If restoration is contraindicated, extraction followed by orthodontic management of the resulting space may be required for space closure or prosthetic replacement.

The next question has to do with the orientation of the tooth. Rotated or poorly angulated premolars usually indicate a failure in normal root resorption of the primary molar. A tooth directed horizontally or apically will not erupt into occlusion without guidance. One should consider orthodontic traction[30] or autotransplantation.[28, 29] A decision to monitor — not to treat immediately — should be considered if further root development may improve the crown position.

A delay in eruption of a succedaneous tooth may be related to the condition of the primary teeth, such as ankylosis or an incomplete resorptive pattern of the primary tooth. Both may indicate a need to extract the primary tooth — or a more conservative approach — to wait for the exfoliation of the primary tooth. Ankylosis or infraocclusion of a primary molar is frequently due to fusion of the primary tooth root to the surrounding bone or due to other causes such as:

- Disturbed local metabolism
- Gaps in the periodontal membrane
- Local mechanical trauma
- Localized infection
- Chemical or thermal irritation
- Local failure of bone growth
- Abnormal pressure from the tongue.[2–5]

Complications that can result from infraocclusion of primary molars include tipping of the neighboring teeth, loss of space, overeruption of the antagonist or posterior (lateral) openbite.[9, 10, 31] In addition, infraoccluded primary molars do not respond to orthodontic forces, so early intervention by extracting the severely infraoccluded primary molar and instituting space-regaining therapy may be indicated.

Frequently, the space may not be adequate for the succedaneous tooth to erupt. Occasionally, when the primary molar is prematurely lost, space regaining is indicated. Examine the entire malocclusion — not merely the local crowding — or the clinician may proceed with space regaining to realize later the case requires extraction of permanent teeth.

Finally, consider the overlying soft tissue. Delayed eruption may be due to overlying soft tissue. The ridge area masticatory mucosa is dense and may be resistant to penetration.[32] Removing soft tissue from the occlusal surface to create a hole approximately the diameter of the unerupted tooth and maintaining patency may allow the tooth to erupt into the oral cavity. Quite frequently, orthodontic traction is required to assist or hasten eruption through the hole. If the unerupted tooth exhibits no physiologic mobility at time of exposure, the tooth will most likely resist orthodontic traction, eruption, or guidance.[31] In that case, extraction is

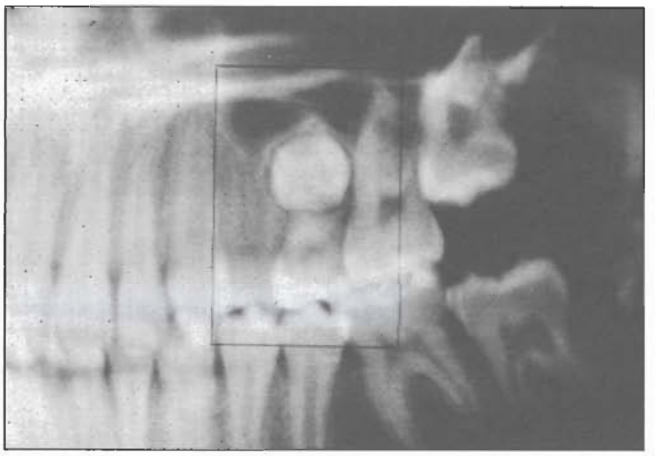

Fig 2A. Picture of the maxillary left second primary molar area taken from a panoramic radiograph of an 11-year 6-month-old patient. The premolar appeared to be angled with the occlusal surface toward the buccal.

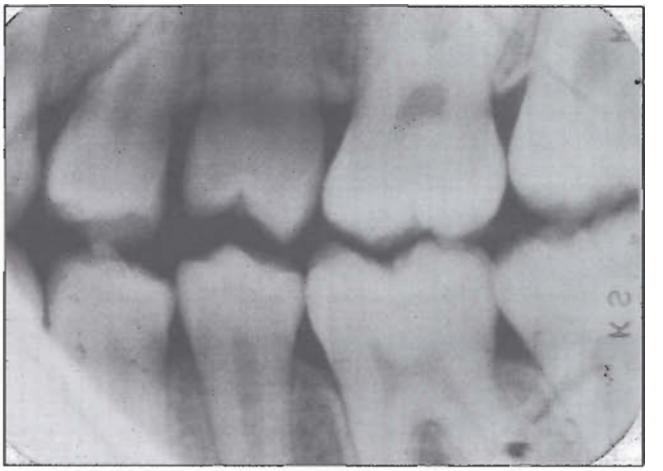

Fig 2B. Radiograph of the same area of the same patient 21 months after extraction of the primary molar. The premolar erupted, without any assistance, into occlusion in a 90° rotated position.

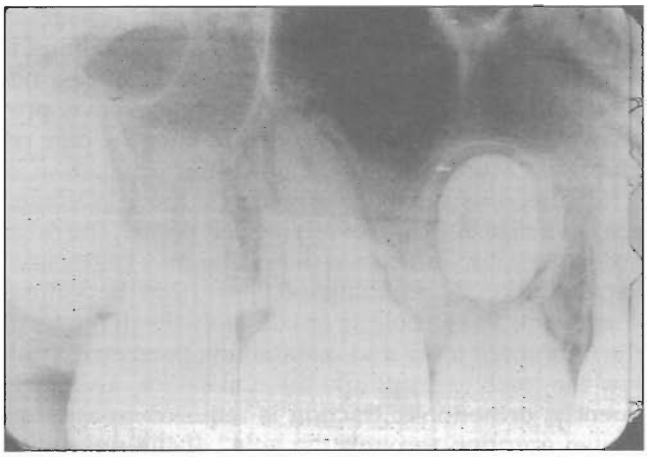

Fig 3A. Radiograph of a left maxillary retained second primary molar with malposed second premolar (6-6-82). Orthodontic appliances are in place.

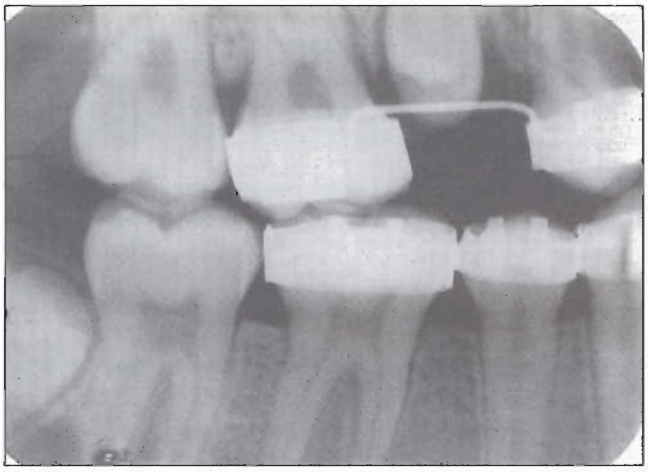

Fig 3B. Radiograph of same area 18 months later (12-9-83). After extraction of the primary molar the opening was maintained. Premolar was erupting unassisted.

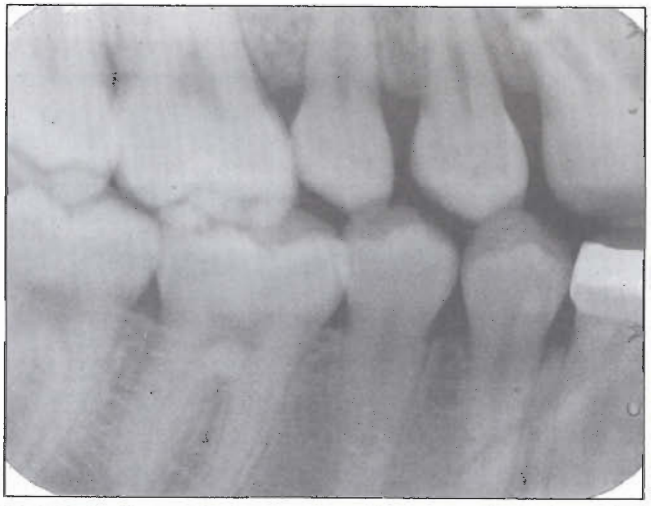

Fig 3C. Radiograph of same area after premolar had erupted into occlusion during the orthodontic retention phase (7-31-84). The maxillary second premolar erupted without any force being applied to it.

indicated since placing a restoration to gain occlusal contact would create an unfavorable crown-to-root ratio, undesirable coronal form, and periodontal relationship.

Case reports

Case 1

An 11-year 6-month-old female seen for a dental recall appointment had a retained maxillary left second primary molar in a Class I dental occlusion. The unerupted premolar appeared to be positioned in such a way that the occlusal surface was directed perpendicularly buccally (Fig 2A). The primary molar was extracted approximately two weeks later. The socket was curetted well and the opening was maintained with iodoformed gauze. No space gaining was needed, and orthodontic care was applied. The premolar erupted into occlusion, but in a 90° rotated position (Fig 2B).

Case 2

A 12-year-old female presented with a Class II, division 1 malocclusion with crowding in the maxillary arch, a slight deep bite, and retained maxillary left second primary molar (Fig 3A). Apical to the retained primary tooth was a malposed second premolar circumscribed by a well-defined radiolucency (wider than a normal periodontal ligament space) and a well-defined "lamina dura." Further radiographic assessment revealed no root formation. Orthodontic treatment was initiated with fixed appliances. No attachment of appliances was made to the primary tooth. Space was increased as Class II correction was continued. The maxillary left second primary molar was extracted and the socket area packed with sterile orthopedic plaster. Plaster was left in place for approximately 2 weeks. The second premolar tooth was allowed to erupt through the patent area (Fig 3B). No orthodontic attachment was placed on the premolar and no force was applied. Active orthodontic treatment was completed and retainers were placed. Adequate space was developed for the premolar. The premolar was left to continue its independent eruption. Four and a half months later the premolar was in occlusion (Fig 3C).

Case 3

A 9-year-old female was referred to the pediatric dentistry/orthodontic clinic for consultation. Clinical and radiographic examination revealed precocious eruption of the maxillary left second premolar, and a blocked maxillary right second premolar due to premature loss of the second primary molar (Fig 4A). Treatment recommendations included space regaining in the maxillary right quadrant to allow eruption of the second premolar. A removable appliance with finger spring was used to distalize the maxillary right first molar. Four years later, all permanent teeth were in occlusion except the over-retained and submerged

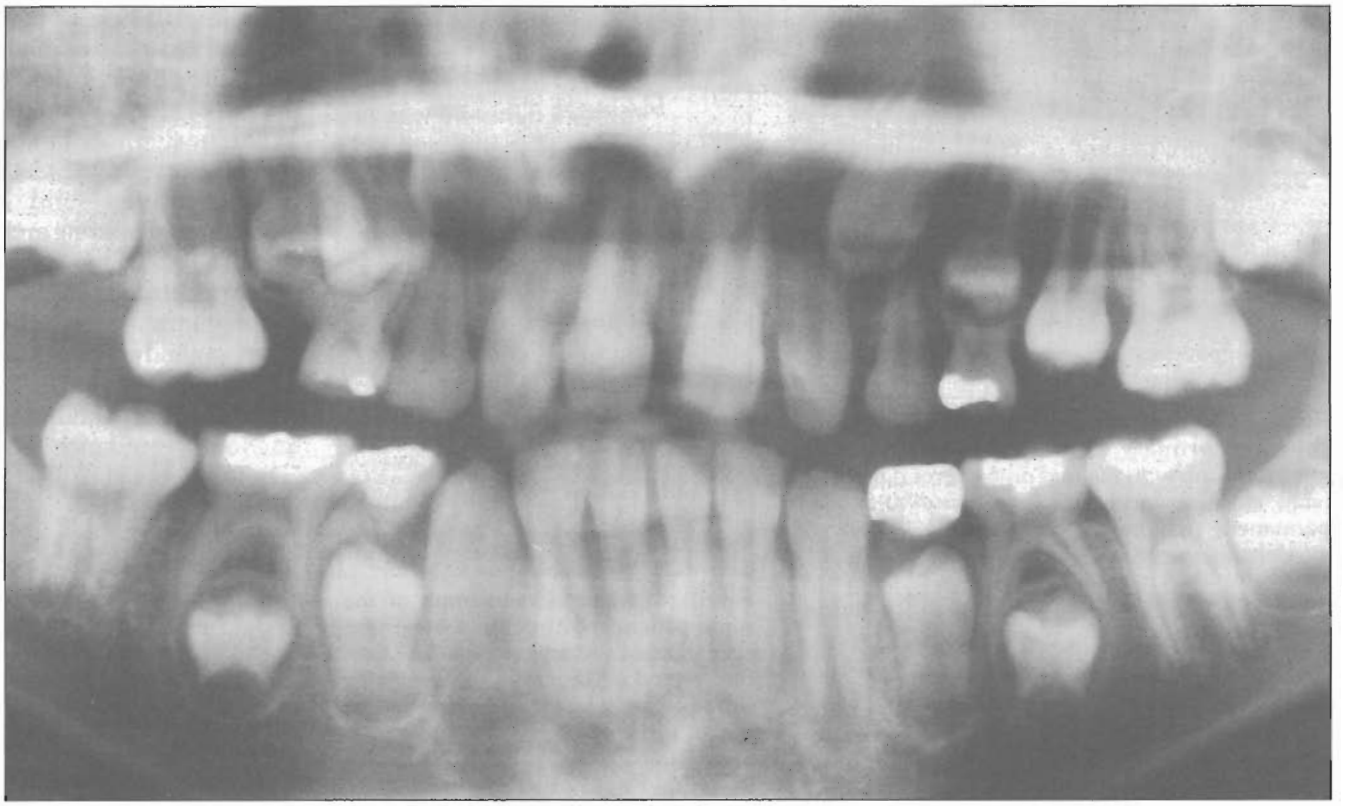

Fig 4A. Panoramic radiograph of a 9-year-old female showing precocious eruption of the maxillary left second premolar and blocked-out maxillary right second premolar due to premature loss of the second primary molar.

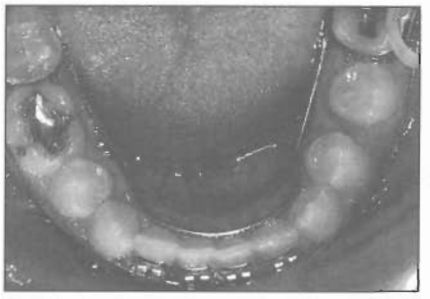

Fig 4B. Occlusal view of the same patient four years later with all permanent teeth in occlusion except the over-retained mandibular right second primary molar.

Fig 4C. Periapical radiograph of the same patient showing an unerupted mandibular second premolar with ankylosed primary second molar.

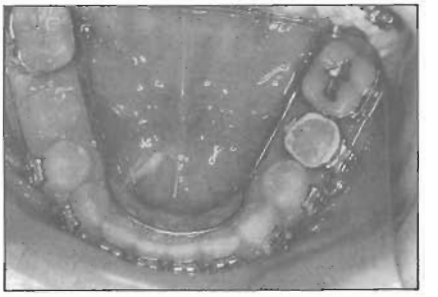

Fig 4D. Occlusal view of the same patient 6 months after extraction of the primary molar showing eruption of the premolar without orthodontic guidance or traction.

mandibular right second primary molar (Fig 4B). A periapical radiograph revealed an unerupted premolar with ankylosed second primary molar (Fig 4C). A lower lingual holding arch was placed as a space maintenance appliance and the patient was referred for extraction of the primary molar. Six months later, the second premolar erupted into occlusion unaided (Fig 4D). Comprehensive orthodontic treatment was completed.

Case 4

A 9-year-old girl presented to the pediatric dentistry/orthodontic clinic with a chief concern of a missing primary molar. Clinical examination revealed that all primary teeth were present in functional occlusion except for the mandibular right second primary molar (Fig 5A). A panoramic radiograph disclosed the presence of a primary molar in severe infraocclusion with the bud of the second premolar lying close underneath. The root of the succedaneous premolar bud was less than half formed and the crown was tipped distally toward the permanent first molar. The mandibular right permanent first molar was mesially tipped and overlapping the primary second molar.

Treatment recommendations included space regaining, molar uprighting, and distalization of the man-

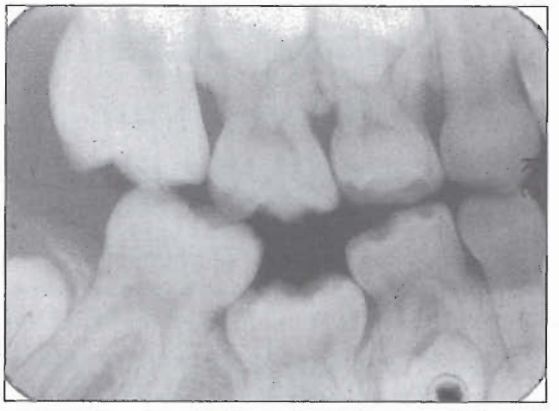

Fig 5A. Bite-wing radiograph of a 9-year-old female showing primary second molar in severe infraocclusion with the bud of the second premolar lying close underneath. The mandibular right permanent first molar was mesially tipped and overlapping the primary second molar.

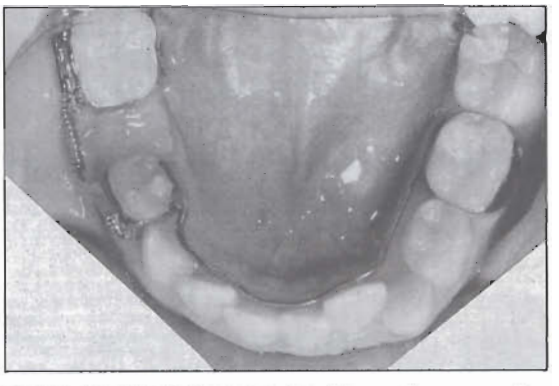

Fig 5C. Occlusal view showing the appliance used to regain space by molar uprighting.

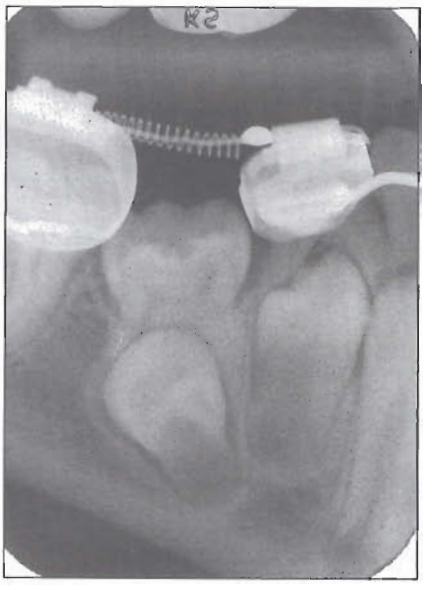

Fig 5B. Periapical radiograph of the same patient showing the roots of the succedaneous premolar were less than half formed and the crown was angulated distally towards the permanent first molar.

Fig 5D. Radiograph taken two years later showing the eruption of premolar into occlusion with orthodontic guidance or traction.

dibular right permanent first molar with a fixed appliance while awaiting development of the succedaneous tooth. Periodic surveillance to determine the need to extract the secondarily retained primary molar was required. The mandibular first permanent molars were banded with buccal tubes and gingival hooks. Mandibular premolar bands with welded brackets were adapted to the primary first molars. A lower lingual holding arch was fabricated from the mandibular right primary first molar to the permanent first molar on the opposite arch. The initial wire was a 0.0175 braided and stopped arch wire. Three weeks later, an 0.016 stopped arch wire was inserted. Six weeks later, a stopped 0.018 wire with compressed coil was placed on the arch wire and inserted between the primary first molar and the permanent first molar. Reactivation was accomplished three times. Total treatment time was 5 months (Fig 5B).

Five months after initiating orthodontic treatment, the second primary molar was removed due to the poor angulation of the succedaneous premolar. After the surgical site of the ankylosed primary molar healed, all bands and brackets on all teeth were removed, and a lower lingual holding arch space maintenance appliance was placed (Fig 5C). Two years later, the premolar had erupted into occlusion uneventfully without any orthodontic traction or guidance (Fig 5D).

Conclusions

An unerupted premolar is common. Failure to detect and analyze the problem may lead to unnecessary space loss, crowding, or collapse in the dental arch. A diagnostic scheme is presented to facilitate diagnosis of the unerupted premolar condition. Important observations to make in the diagnosis and treatment planning for unerupted premolars are:

1. Presence of unerupted premolar
2. Space available for its eruption
3. Presence, position, status and condition of primary molar
4. Viability of premolar form, eruptive potential and orientation
5. Presence and status of overlying bone and/or soft ridge musoca.

Dr. Burch is professor, department of orthodontics and Dr. Ngan is associate professor, department of orthodontics, The Ohio State University, Columbus. Dr. Hackman is in private practice in Columbus, Ohio.

1. DiSalvo NA: Evaluation of unerupted teeth: orthodontic viewpoint. J Am Dent Assoc 82:829–35, 1971.
2. Sullivan B: Observations on submerged primary molar teeth. N Z Dent J 72:224–28, 1976.
3. Krakowiak FJ: Ankylosed primary molars. ASDC J Dent Child 45:288–92, 1978.
4. Messer LJB, Cline JT: Ankylosed primary molars: results and

treatment recommendations from an eight-year longitudinal study. Pediatr Dent 2:37–47, 1980.
5. Kurol J, Thilander B: Infraocclusion of primary molars and the effect on occlusal development, a longitudinal study. Eur J Orthod 6:277–93, 1984.
6. Kurol J, Koch G: The effect of extraction of infraoccluded deciduous molars: a longitudinal study. Am J Orthod 87:46–55, 1985.
7. Ben-Bassat Y, Brin I, Fuks AB: Occlusal disturbances resulting from neglected submerged primary molars. ASDC J Dent Child 58:129–33, 1991.
8. Raghoebar GM, Boering G, Stegenga B, Vissink A: Secondary retention in the primary dentition. ASDC J Dent Child 58:17–22, 1991.
9. Douglass J, Tinanoff N: The etiology, prevalence, and sequelae of infraclusion of primary molars. ASDC J Dent Child 58:481–83, 1991.
10. Becker A, Karnei-R'em RM: The effects of infraocclusion: Part 1. Tilting of the adjacent teeth and local space loss. Am J Orthod Dentofacial Orthop 102:256–64, 1992.
11. Becker A, Karnei-R'em RM: The effects of infraocclusion: Part 2. The type of movement of the adjacent teeth and their vertical development. Am J Orthod Dentofacial Orthop 102:302–9, 1992.
12. Grover PS, Lorton L: The incidence of unerupted permanent teeth and related clinical cases. Oral Surg Oral Med Oral Pathol 59:420–25, 1985.
13. Azaz B, Steiman Z, Koyoumdjisky-Kaye E, Lewin-Epstein J: The sequelae of surgical exposure of unerupted teeth. J Oral Surg 38:121–27, 1980.
14. Salzmann JA: Orthodontics: principles and prevention. Philadelphia: JB Lippencott Co, 1957, pp 297.
15. Konstat MM, White GE: Ankylosed teeth: a review of the literature. J Mass Dent Soc 24:74–78, 1975.
16. Biederman W: The problem of the ankylosed tooth. Dent Clin North Am July:409–24, 1968.
17. Andlaw RJ: Submerged deciduous molars: a review, with special reference to the rationale of treatment. J Int Assoc Dent Child 5:59–66, 1974.
18. Gorelick L, Geiger AM: Direct bonding in the management of an ankylosed second deciduous molar. J Am Dent Assoc 95:307–9, 1977.
19. Rubenstein L, Wood AJ, Camm J: An ectopically impacted premolar with a radiolucent defect. J Pedod 14:50–52, 1989.
20. Strock MS: A new approach to the unerupted tooth by surgery and orthodontics. Am J Orthod 24:626–34, 1938.
21. Gwinn CD: Exposure of unerupted upper cuspids for orthodontic purposes. J Am Dent Assoc 32:265–70, 1945.
22. Lappin MM: Practical management of the impacted maxillary cuspid. Am J Orthod 37:769–78, 1951.
23. Holland DJ: A technique of surgical orthodontics. Am J Orthod 41:27–44, 1955.
24. Sleeper EL: Surgical orthodontic technique and case reports. Alpha Omegan 49:110–16, 1955.
25. Northway WM, Konigsberg S: Autogenic tooth transplantation: the "state of the art". Am J Orthod 77:146–62, 1980.
26. Lownie JF, Cleaton-Jones PE, Fatti P, Lownie MA: Autotransplantation of maxillary canine teeth: a follow-up of 35 cases up to 4 years. Int J Oral Maxillofac Surg 15:282–87, 1986.
27. Schatz JP, Joho JP: Aurotransplantations and loss of anterior teeth by trauma. Endod Dent Traumatol 9:36–39, 1993.
28. Andreasen JO, Paulsen Hu, Yu Z, Schwartz O: A long-term study of 370 autotransplanted premolars, Part III. Periodontal healing subsequent to transplantation. Eur J Orthod 12:25–37, 1990.
29. Andreasen JO, Paulsen HU, Yu Z, Bayer T: A long-term study of 370 autotransplanted premolars, Part IV. Root development subsequent to transplantation. Eur J Orthod 12:38–50, 1990.
30. Gensior AM, Strauss RE: The direct bonding technique applied to the management of the maxillary impacted canine. J Am Dent Assoc 89:1332–37, 1974.
31. Proffit WR, Vig KWL: Primary failure of eruption: a possible cause of posterior open-bite. Am J Orthod 80:173–90, 1981.
32. Goho C: Delayed eruption due to overlying fibrous connective tissue. ASDC J Dent Child 54:359–60, 1987.