Interdisciplinary treatment to optimize facial aesthetics

Orthodontists today are faced with more adult patients seeking treatment. Many of these patients do not have the benefit of orthodontic treatment during their teenage years. With the advent of ceramic brackets, reliable adhesive systems, and clear orthodontic aligners, adult patients are more eager to seek orthodontic treatment because the appliances are less conspicuous, more acceptable in social settings, and the treatment procedures are less arduous.

By Prof Peter Ngan, Prof Elizabeth Kao, Dr Hal Reed, Dr Bryan Weaver and Prof Stephen H Wei

The presence of abraded or worn dentition, decrease bony support, temporo-mandibular joint (TMJ) dysfunction and skeletal problems that cannot be modified since growth has completed, are examples of challenges in the orthodontic treatment of adults. Orthodontists often have to resort to less than ideal treatment to provide an acceptable result. A comprehensive approach utilizing the combined expertise of a team of specialists and the general dentist is essential for the successful outcome.

The objective of this article is to discuss a few principal guidelines in the treatment planning for adult orthodontic cases. The treatment of a young adult patient is reported to illustrate the importance of sequencing treatments from one discipline to the other, the communication among the team players, and the benefits of working together in an interdisciplinary approach.

Establish realistic treatment objectives

The first guideline in treatment planning for multidisciplinary cases is an accurate diagnosis of all the problems. Are there any skeletal problems in the three planes of space that may prevent the attainment of an ideal occlusion? Are there any periodontal or TMJ problems that may compromise treatment? Are there any abraded or worn teeth that may be related to parafunctional habits? Once the problems are identified, the next step is the establishment of realistic treatment objectives Not uncommonly, In adult patients with compromised dentition and occlusion, one has to establish treatment objectives that are realistic biomechanically, restoratively, and economically and above all, accepted by the patient.[1] For example, in closing a large edentulous space left from a missing mandibular first molar, one may consider an implant, a fixed or removable prosthesis instead of orthodontic space closure which may compromise the root length and tooth vitality. However, if the patient decides on orthodontic correction, one must consider whether it is biomechanically feasible to close a 10 mm space. If it can be closed, are the remaining teeth strong enough to act as anchors for such movement. With the advent of retromolar implants[2] and microscrew implants[3], it is now possible to a close large edentulous space orthodontically using these implants as orthodontic anchorage.

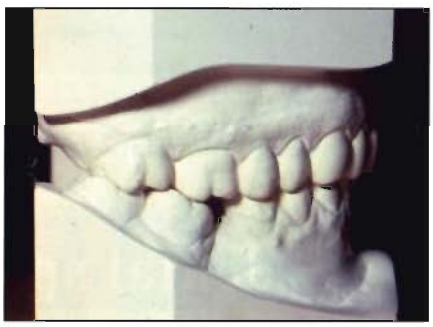

Fig. 1: Diagnostic model of a 40 year old patient with previously extracted mandibular left permanent first molar, now presenting with mesially tipped mandibular second and third molars. In addition, the opposing first molar was supererupted into the edentulous space.

Envision the Final Treatment Result

The second guideline in treatment planning for multidisciplinary cases is to envision the final treatment result. In adult patient with more compromised occlusion and dentition, one may find it difficult to foresee the final result. It is similarly challenging for the restorative dentist to visualize the final result of orthodontic treatment. For patients who

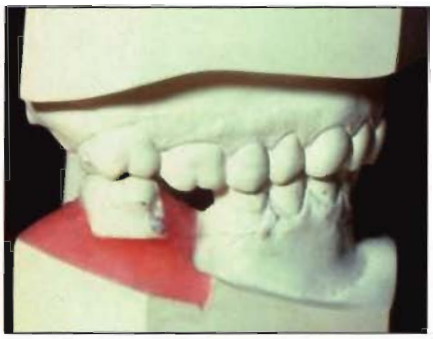

Fig. 2: Diagnostic set up of patient showing how much pontic space can be gained from extraction of the mandibular third molar and uprighting of the mandibular second molar.

Fig. 3: Model of patient showing final result after orthodontic treatment.

require adjunct treatment such as orthognathic surgery, endodontics therapy or periodontics, the patient may want to know the benefits of each phase of the treatment.

It will be helpful for the restorative dentist to seek the opinion of various specialty experts and present to the team and to the patient a diagnostic set up which simulate the possible tooth movement and the final position of the teeth prior to restorative dentistry.

Figure 1 shows an example of a 40-year old patient with mesially tipped mandibular second and third molars. In addition, the opposing first molar had super-erupted into the edentulous space. The possible treatment options may include: (1) no treatment, which must always be offered, (2) orthodontic space closure and a crown to correct the supererupted maxillary molar, (3) extraction of the mandibular third molar and uprighting the second molar to be used as a fixed prosthesis abutment. A diagnostic set up is beneficial to show the team how much pontic space can be gained from molar uprighting as well as the interdigitation of teeth after orthodontic treatment (Figure 2). The diagnostic set up enables the patient to visualize the final treatment result before investing his or her time in the entire treatment. Figure 3 shows the final result after orthodontic treatment. Proper space for pontics or implant can be readily measured.

Determine the Sequence of Treatment

Many orthodontic/restorative cases require adjunct treatment such as periodontics, endodontics and orthognathic surgery. As the number of specialists increase in the treatment, the complexity of the case increases. Therefore, the third guideline is for the interdisciplinary team to meet and outline the sequence of treatment for the patient.

Gingival aesthetics Management

Gingival margin formations can make a world of difference to the esthetic outcome of a smile upgrade. It is easy to overlook gingival esthetics in treatment planning for adult orthodontic cases. The fourth guideline is to evaluate gingival esthetic at the beginning of treatment and during each step in the sequence of treatment. Two of the most common unaesthetic situations that may develop during orthodontic treatment include gingival smile and gingival height discrepancies.

Gingival smile

Ideally, in unstrained smiling, the position of the upper lip should rise to a level at or slightly apical to the gingival margins of the maxillary central incisors. In this situation, about 1 to 2 mm of gingiva will be apparent when the patient smiles.[4] Patients who show more than 2mm of gingiva upon smiling may appear unaesthetic and are often labeled as "gingival smile". The causes of gingival smile may be related to excessive maxillary growth, shorter than normal upper lip, or more than normal eruption of the maxillary teeth.[5]

If all the maxillary teeth have over-erupted, the treatment requires orthodontics or orthognathic surgery to move the entire maxilla apically.[6] If there is delayed apical migration of the gingival margin over the maxillary anterior teeth, the proper treatment will be gingival surgery to move the gingival margin apically toward the cemento-enamel junction. Normally, as teeth erupt during childhood and adolescence, the gingival margin migrates apically until it reaches its normal adult position. In most adult patients, the gingival margin is positioned about 1mm coronal to the cemento-enamel junction.[7] However, in some patients the gingival tissue may be thick and fibrotic. Thick tissue tends to migrate more slowly than thin gingival tissue. In these patients, the first step is to probe the gingival sulci of their maxillary anterior teeth. The sulcular depth should be about 1 mm, and the cemento-enamel junction should be at the depth of the sulcus.

Gingival Margin Discrepancies

The gingival margin of the maxillary anterior teeth plays an important role in the facial esthetics. The gingival height must be in proportion to maintain symmetry throughout the smile. The gingival margin of the canines and centrals should be at the same height with the lateral incisor positioned approximately 0.5-1 mm incisally from them. In addition, there should be a papilla between each tooth.[8]

In patients who have gingival margin discrepancies between adjacent teeth, the problem could be caused by abrasion of the incisal edge or delayed migration of the gingival tissue. The treatment of choice is either orthodontic movement to reposition the gingival margin or surgical correction of gingival margin discrepancies. Clinicians should

Fig. 4: Extraoral photographs of a 19 year old patient presenting with a concave facial profile and facial asymmetry.

Fig. 5: Intraoral photographs of the same patient showing a Class III molar relationship with anterior and posterior crossbites.

Fig. 6: Lateral cephalometric radiograph of the same patient showing severe anteroposterior as well as vertical jaw discrepancies.

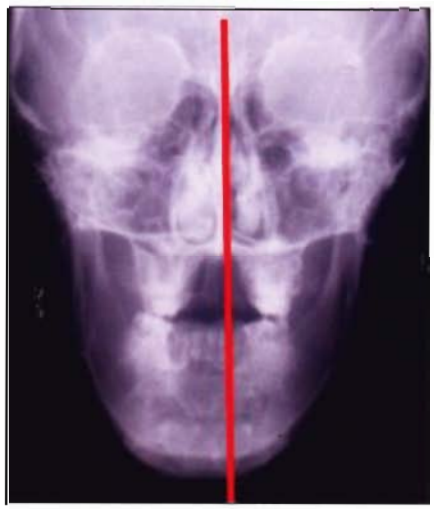

Fig. 7: Anteroposterior cephalometric radiograph of the same patient showing skeletal asymmetry.

perform the following diagnostic procedures to decide on the treatment options. Firstly, evaluate the relationship of the gingival margin of maxillary incisors with the patient's smile or lip line. If the patient does not show the gingival margin discrepancy upon smiling, no treatment is necessary. Secondly, evaluate the labial sulcular depth of the incisors. If a tooth that appears shorter has a deeper sulcus, gingivectomy may be helpful to move the gingival margin apically. Thirdly, evaluate the clinical crown of the incisors and see whether the incisal edge has been abraded. Orthodontic eruption of the incisor can bring down alveolar bone as well as the gingival margin.[9]

Case Report

T.P. is a 19 year old Caucasian male with a history of previous orthodontic treatment, now presenting with chief concerns of "crooked jaws and a loose maxillary incisor". Extraoral examination revealed a concave facial profile characterized by a combination of maxillary deficiency and mandibular prognathism- (Figure 4). The anterior facial photo revealed a significant facial asymmetry with the mandible shifted to the patient's right side. There was no centric relation discrepancy on closure. Patient displayed excessive gingival tissue during natural unforced smile. Vertical facial analysis revealed an increase lower face height with hyperdivergent mandible. Intraoral examination revealed a Class III molar relationship with anterior and posterior crossbites (Figure 5). Patient had congenitally missing maxillary right and left lateral incisors and retained primary right maxillary lateral incisor. The maxillary and mandibular first premolars were extracted from previous orthodontic treatment. The permanent teeth were in good alignment but with short clinical crowns. The TMJ function was within the normal range of motion and no pain was reported on palpation.

The cephalometric radiograph indicated a skeletal Class III relationship due to a retrusive maxilla (SNA = 76°)

and a protrusive mandible (SNB = 82°, Figure 6). The lower face height was excessive in proportion to the total facial height (58% of total facial height). The mandibular plane angle was steep (43° to SN) and the chin projection was deficient. Upper incisal inclinations were within normal limit (Upper incisor to NA = 24°) and the lower incisors were retroclined (Lower incisor to NB = 12°). The antero-posterior cephalometric radiograph indicated significant skeletal asymmetry with the chin deviated to the patient's right side for 4 mm (Figure 7).

Fig. 8: Intraoral photographs showing pre-surgical orthodontic treatment to decompensate dentition.

Fig. 9: Post-surgical lateral cephalometric radiograph showing the result of orthognathic surgery.

Fig. 10: Post-surgical anteroposterior cephalometric radiograph showing the improvement in skeletal symmetry after orthognathic surgery.

Treatment Objectives

The objectives of the treatment were to establish a reasonable occlusion to improve the patient's ability to eat and chew. The patient was not particularly concerned about his facial esthetics. The dentition was to be decompensated in preparation for orthognathic surgery. The gingival smile was to be addressed with either orthognathic surgery or periodontal surgery. The congenitally missing teeth were to be replaced by implants or fixed prosthesis.

Treatment Alternatives

The following treatment plan was presented to the patient: Comprehensive pre-surgical orthodontic treatment to decompensate dentition in preparation for orthognathic surgery to reduce lower facial height, normalize anteroposterior skeletal relationship, and increase chin prominence. While the materials and techniques utilized in the fabrication of a restoration will directly influence the treatment outcome, the desires of the patient, anticipated longevity of the restoration, possibility of complications and cost were presented to the patient. The patient declined the implant option because he was leaving for a new job in a few months. The patient did not desire removable prosthesis and preferred a more conservative approach to two 3-unit fixed prostheses. One of the treatment options available was an adhesive, fiber-reinforced resin fixed partial denture.[10,11] The choice presented is very similar to the established "Maryland" bridge. Traditionally, "Maryland" bridges use metal retaining wings to maintain a pontic, but these wings have shown to be associated with retention problem because of its rigidity. In young patients, in particular, metal may show through the more translucent enamel and dentin, creating an esthetic problem.[12-14] Although the fiber reinforced resin bridge is a recent development, the preparation and fabrication guidelines are well established. Preliminary investigations support the clinical application of this technique.[11,15] The use of fiber reinforcement increases the flexural strength of resin systems. The woven fibers can resist stress in different directions and allow the restoration to retain flexibility and not cause complete fracture or debonding of the wings when stressed.[16,17] The only concern in this case is that the available enamel surface for bonding is relatively small because of excessive gingival growth. In general, women tend to show slightly more gingival than man, and a slight show of gingival can be considered to be a feminine trait.[4] The patient's central incisors measured about 9 mm in length and 8 mm in width, which was shorter than the norm and wider than the length: width ratio.[18-20] The resulting pontic will give a square aspect ratio if restored as is. Esthetic crown lengthening was proposed to increase clinical crown

Fig. 11: Extraoral and intraoral photographs showing the improvement in facial profile and occlusion after orthognathic surgery.

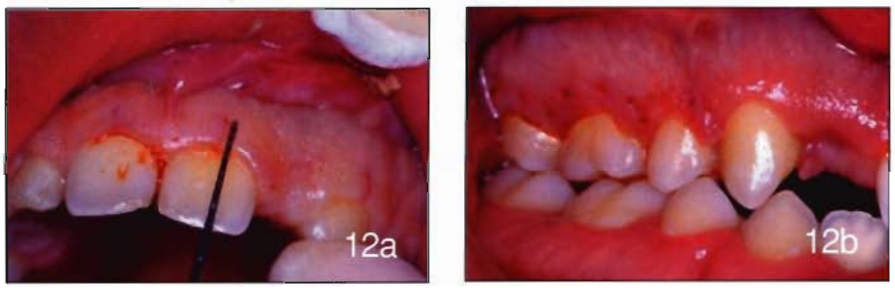

Fig. 12a-b: A periodontal probe was used to create bleeding points and map out the initial surgical incision.

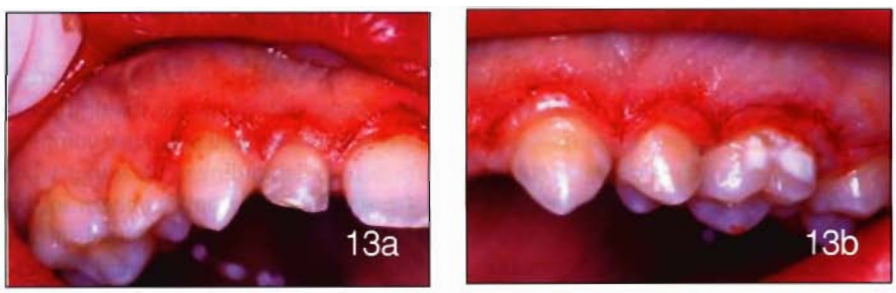

Fig. 13: Periodontal procedure to preserve the natural wavy outline of the gingival margin and the interproximal papilla.

height and to increase the surface area for bonding. The decision between flap surgery and osseous re-contouring or orthodontic extrusion was discussed according to how much attached gingiva were available, the location of the cemento-enamel junction, and the final location of the incisal edge.

Treatment Progress

Orthodontic Phase

Orthodontic treatment was started to decompensate the maxillary and mandibular dentitions in preparation for orthognathic surgery (Figure 8). The first and second molars in the maxillary and mandibular arches were banded. Edgewise brackets (0.022 x 0.028 in) were bonded on the remaining teeth. The maxillary and mandibular arches were leveled and aligned with progression of archwires until reaching the size of 0.019 x 0.025 stainless steel wires. The maxillary right primary lateral incisor was kept for esthetic purpose.

Surgical Phase

Orthognathic surgery procedures consisted of a maxillary Lefort I osteotomy with differential impaction of 3 mm posteriorly and advancement of 4 mm (Figures 9 and 10). A vertical ramus osteotomy was used for mandibular setback into the plane of occlusion. A vertical reduction and advancement genioplasty was utilized to decrease the long lower face height and provide better facial symmetry. Figure 11 shows the extraoral and intraoral photographs of patient after completion of orthognathic surgery and orthodontic treatment.

Tissue management

For esthetic crown lengthening, a complete periodontal examination was performed. In addition, an evaluation of the patient's smile, the gingival planes in relation to the relaxed and smiling lip position and a determination of the patient's periodontal biotype were carried out as described by Sclar.[21] Probe depths were in the 2–3 mm range anteriorly, and 2–5 mm range posteriorly. The periodontal tissue appeared to be thick, fibrotic and hyperplastic. Approximately 2–3 mm of gingival tissue was visually apparent with a relaxed smile. In evaluating the amount of gingival tissue to be removed, a measurement of the width of the central incisors allowed the periodontist to estimate the proposed length, as the width is normally 75-80 % of the length.[22] The proposed length of the lateral incisors was planned to be 1 mm less on both the gingival and incisal aspects in relation to the centrals, and the cuspids were approximately the same length as the central incisors.[23]

A final consideration was given for

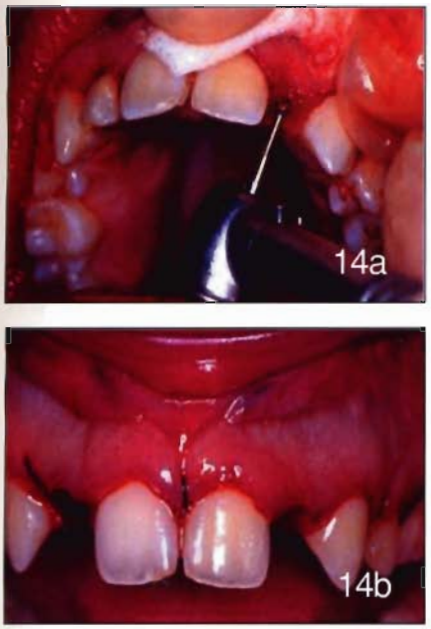

Fig. 14a-b: A #8 round bur was used to create an ovate pontic site after extraction of the primary lateral incisor.

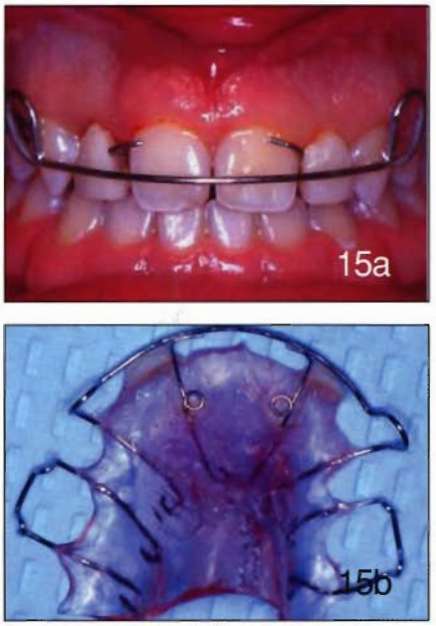

Fig. 15a-b: Contouring the denture teeth of the flipper to allow healing of the ovate pontic site. Finger springs were added to the flipper to adjust dental midline as needed.

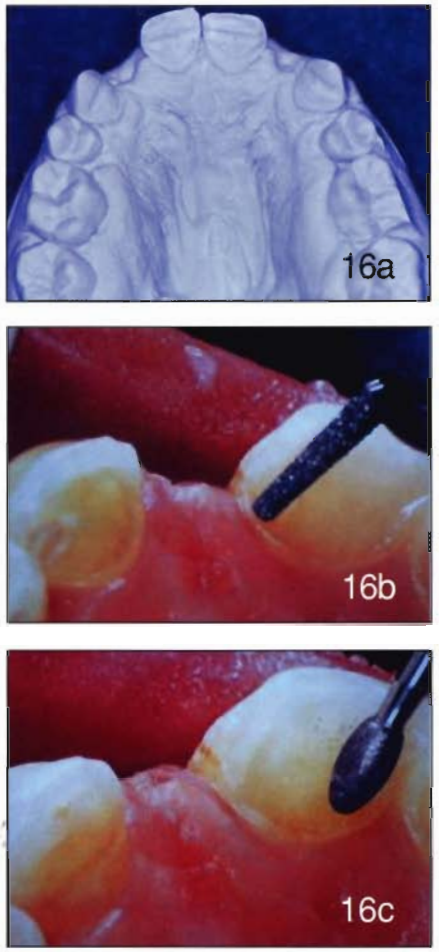

Fig. 16a-c: Preparation of the abutment teeth to allow adequate clearance.

the biologic width of the tissue remaining after surgery. An accommodation was planned for a minimal combined width of 2-3 mm of connective tissue and junctional epithelium, as well as a 0.7-1 mm sulcus depth in the maxillary anterior region.[24] Using these proportions as an estimate, it was determined that the patient had 2–3 mm of hyperplastic tissue in the maxillary anterior region, and by sounding the bone, it was revealed that that there would be adequate amount of distance from the proposed gingival margin to the alveolar crest to allow for biological width.

In this patient, since there was a wide band of keratinized tissue throughout the mouth of the patient, the crown lengthening procedure was accomplished by gingival excision without osseous re-contouring. After mapping out the initial surgical incision by measuring the length of the teeth, a periodontal probe was used to create a bleeding point at the height of contour before making the incision (Figure 12). To preserve the natural wavy outline of the gingival margin and the interproximal papilla, partial thickness flap with internal bevel was performed. After removal of the collar of gingiva, the roots were instrumented and the mucogingival flap was positioned apically to maintain a 3 mm subgingival space for the biological width. The procedure was extended to the molar segment to create symmetry and a harmonious gradation (Figure 13). Osseous contouring facilitated tuberosity reduction, allowing the patient to continue wearing his transitional appliance during the healing phase. Patient was instructed to use 2% chlorhexidine gluconate solution rinse post surgery for 7-10 days.

Pre-prosthetic phase

During the tissue management phase, the retained right primary lateral incisor was extracted. A #8 round diamond bur was used to create an ovate pontic site in the left side where the tooth has been lost for a long time (Figure 14). The ovate pontic presents the illusion that the pontic is emerging from the tissue as would a natural tooth, with at least 2 mm of soft tissue remaining above the osseous crest. The gingival contour of the denture teeth on the patient's existing removable flipper was modified with additional acrylic resin to allow healing around the ovate pontic sites (Figure 15). A finger spring was built in the removable appliance and when activated, it would correct the midline shift.

Prosthetic phase

After 4 weeks of healing, the abutment teeth were prepared to allow adequate occlusal clearance of 1.5 mm for the retainer wings. Since the patient did not have a deep bite nor steep anterior path of guidance, minimal tooth structures had to be reduced on the

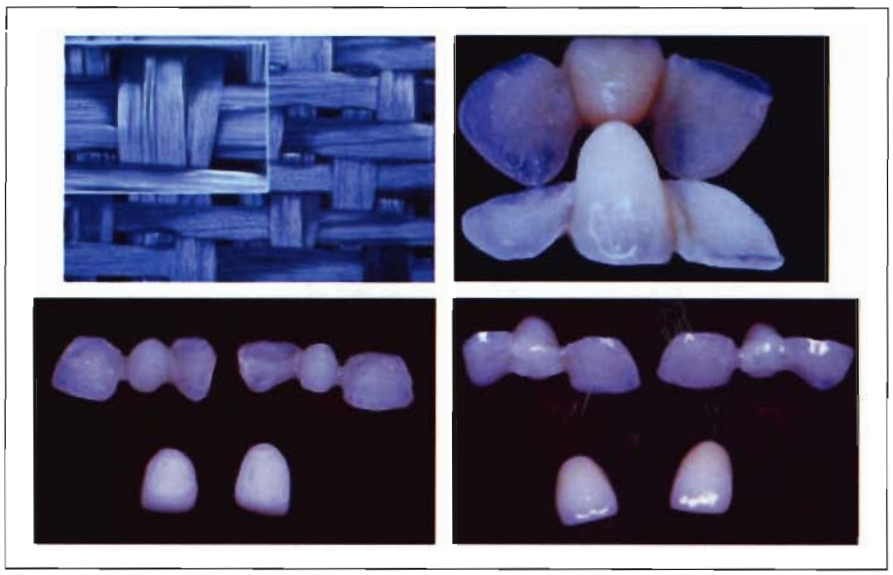

Fig. 17: Resin framework and porcelain veneer for prosthetic replacement of the missing lateral incisors.

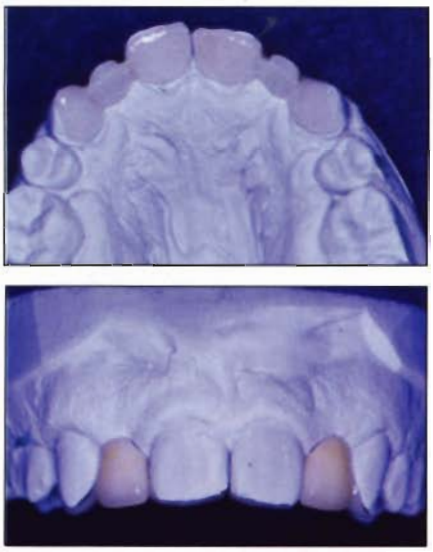

Fig. 18a-b: Evaluation of the resin framework and porcelain veneer on stone die for proper margin fit and path of seating.

lingual. The lingual preparation extended to the proximal surfaces adjacent to the pontic site and within 1 mm of the proximal line angle and incisal edge. A 0.5 mm deep proximal box was placed just lingual to the proximal height of contour of the edentulous space in order to increase the strength at the connector site. Cervically, the finish line was 1 mm short of the free gingival margin. A 0.5

Fig. 19: Post-restorative facial photograph showing esthetic outcome of the treatment.

mm horizontal groove was placed in the middle of the lingual surface of the abutment teeth to assist in confirming a positive seal of the final restoration (Figure 16). A polyvinylsiloxane impression was taken and sent to the laboratory along with photographs, opposing model and a bite registration. Upon delivery of the final restoration from the laboratory, the resin framework and the porcelain veneers were evaluated on the stone die for proper margin fit and path of seating (Figures 17 and 18).

To prepare the restoration for bonding, the teeth were etched by a 35% phosphoric acid solution for 10 seconds. The acid was rinsed and the tissue surfaces of the restoration was treated with a silane ceramic primer for 60 seconds and air-dried. A thin layer of adhesive resin was painted and air-dried. The tooth preparations were acid-etched with 35% phosphoric acid gel for 20 seconds, rinsed and blotted dry. Multiple coats of bonding agent were applied to each preparation and excess solvents were evaporated with light compressed air. The resin bridge framework was cemented with dual cured adhesive resin. It was held in place with light, even pressure and excess cement was removed with a sable brush and then light cured. After setting, porcelain veneers were tried in with water soluble try-in paste for shade modification. Once the shade was satisfactory to the patient, the internal surfaces of the veneers were etched with hydrofluoric acid, silane primed, painted with thin layer of bonding agent and cemented with dual cured resin cement. Minor occlusal adjustment was performed once the cementation was complete (Figures 19 and 20). Gingivectomy with selected osseous re-contouring was performed in the mandibular arch at a later date to complete the treatment.

Treatment Results

The final photographs and radiographs show an acceptable occlusion and facial profile after orthodontics and orthognathic surgery. The facial asymmetry was corrected and the excess lower face height was reduced to improve the vertical facial proportion. The excess gingival smile was reduced. The clinical crown height was increased with the periodontal procedure to improve the bonding surface area of the abutment teeth and the missing maxillary lateral incisors were replaced with fiber reinforced resin bridges.

Conclusion

As patient's knowledge about esthetics and functions increases, dentists are challenged to provide services that will encompass the well being of the whole patient. The creation of an esthetic smile with proper phonetics, symmetry, balance and function may involve multiple

Fig. 20: Post-restorative intraoral photographs showing esthetic replacement of the missing lateral incisors with fiber-reinforced bridges. Mandibular crown lengthening shows significant gain in clinical crown height.

procedures and disciplines. Correct diagnosis of the case is the key to successful treatment. A successful team involves constant discussions, communications and education in order to arrive at a common vision. Understanding patients by discussing their desires, concerns and values also enables the team to establish customized treatment planning. With the development of new materials and technologies, dentistry today can change people's lives, boost their self-esteem and improve their health status. **DA**

References

1. Kokich VG, Spear FM. Guidelines for managing the orthodontic-restorative patient. Seminars in Orthod 3:3-20, 1997.
2. Roberts WE, Nelsonh CL, Goodacre CJ. Rigid implant anchorage to close a mandibular first molar extraction site. J Clin Orthod 28:693-704, 1994.
3. Kyung HM, Park HS, Bae SM, Sung JH, Kim IB. Development of orthodontic micro-implants for intraoral anchorage. J Clin Orthod 37:321-328, 2003.
4. Vig R, Brundo G. The kinetics of anterior tooth display. J Prosthet Dent 39: 502-504, 1978.
5. Willmar K. On LeForte I Osteotomy. Scand J Plast Reconstr Surg 12:1-68, 1974.
6. Proffit W, Phillips C. Adaptations in lip posture and pressure following orthognathic surgery. Am J Orthod 93:294-302, 1988.
7. Maynard J, Wilson R. Physiologic dimension of the periodontium fundamental to successful restorative dentistry. J Periodontol 50:170-174, 1979.
8. Kokich VG. Esthetics: The orthodontic-periodontic restorative connection. Seminars in Orthod 2:21-30, 1996.
9. Ngan P, Knobloch L. Multidisciplinary and esthetic approach to clinical crown lengthening: Report of a case. Quintessence Int 24: 835-839, 1993.
10. Meyenberg KH, Imoberdorf MJ. The aesthetic challenges of single tooth replacement: a comparison of treatment alternatives. Pract Periodontics Aesthet Dent 9:727-735, 1997.
11. Javaheri DS. Replacement of an anterior tooth with a fiber-reinforced resin bridge; Compend. Contin Educ Dent 22: 68-74, 2001.
12. Barrack G, Bretz WA. A long-term prospective study of the etched-cast restoration. Int J Prosth 6:428-434, 1993.
13. Fienman RA. Conservative anterior tooth replacement using etched porcelain pontics. Pract Periodontics Aesthet Dent 3:21-25, 1991.
14. Williams VD, Thayer KE, Denehy GE et al. Cast metal, resin-bonded prostheses: a 10 year retrospective study. J Prosthet Dent 61:436-441, 1989.
15. Leal FR, Cobb DS, Denehy GE, et al. A conservative aesthetic solution for a single anterior edentulous space: case report and one year follow up, Pract Proced Aesthet Dent. 13:635-41, 2001.
16. Strassler HE, Serio FG. Stabilization of the natural dentition in periodontal cases using adhesive restorative materials. Periodontal Insights 4:4-10, 1997.
17. Iniquez I, Strassler HE Polyethylene ribbon and fixed orthodontic retention and porcelain veneers: solving an esthetic dilemma. J. Esth. Dent.10:52-59, 1996.
18. Bjorndol AM , Henerson WG. Anatomic measurements of human teeth extracted from males between ages of 17 and 21years. Oral Surg. 38:791-803, 1979.
19. Garn SM, Lewis AB, Walenga AJ Maximumk confidence values for the human mesio-distal crown dimentsion. Arch Oral Biol 13:841-849, 1968.
20. Mack PJ. Maxillary arch and central

incisor dimension in a Nigerian and British population sample. J Dent 9:67-70, 1981.
21. Sclar A. Soft Tissue and Esthetic Considerations in Implant Therapy Chicago:Quintessence, 24-29, 2003.
22. Chiche GJ, Pinault A. Artistic and scientific principles applied to esthetic dentistry. In: Chiche GJ and Pinault A. eds. Esthetics of anterior fixed prosthodontics. Chicago: Quintessence; 13-32, 1994.
23. Levin EL. Dental esthetics and the golden proportion. J. Prosthet Dent 40:244-252, 1978.
24. Gargiulo AW, Wentz FM, Orban B. Dimensions and relations of the dentogingival junction in humans. J. Periodontol 32:261, 1961.

Bryan Weaver, D.D.S., M.D. is an Associate Professor and residency director of Oral and Maxillofacial Surgery at West Virginia University School of Dentistry. He is a diplomate of the American Board of Oral and Maxillofacial Surgeons and a past president of the West Virginia Society of Oral and Maxillofacial Surgeons.

Dr. Kao is a Professor in the Department of Restorative Dentistry at West Virginia University School of Dentistry and maintains an active practice in the University's dental faculty practice in Morgantown, West Virginia. A Fellow of the Academy of General Dentistry and a member of the University Advisory Council of the AACD, Dr. Kao lectures to professional organizations and local dental societies. Dr. Kao has published numerous research papers and abstracts on the development and evaluation of composite and glass ionomer materials, microbial and particulate aerosols generated from dental procedures, orthodontic retention, and caries prevention. She holds a U.S. Patent and is the principal investigator in NIDR and ADAHF grants and in several university and dental association development grants. She received the Student Development Award from the American Association for Dental Research and the West Virginia University School of Dentistry.

Harold H. Reed, D.D.S., M.S. is an Associate Clinical Professor in Periodontics at West Virginia University. Dr. Reed earned his D.D.S. at West Virginia University and his M.S. and Certificate in Periodontics at the University of Iowa. He is board eligible and divides his time between private practice in Morgantown, WV and teaching at WVU.

Dr. Peter Ngan is Professor and Chairman, Department of Orthodontics, West Virginia University, School of Dentistry. He is also head of the Division of Pediatric Dentistry at WVU, School of Dentistry. Dr. Peter Ngan holds a dental degree from Harvard University, School of Dental Medicine and Certificates in Orthodontics, Pediatric Dentistry and Hospital Dentistry from the University of Pennsylvania, School of Dental Medicine/ Children Hospital of Philadelphia. He is a Fellow of the American Society of Dentistry for Children, Diplomate of the American Board of Orthodontics and Diplomate of the American Board of Pediatric Dentistry. He has appointed by the Commission on Dental Accreditation of the ADA to serve their commission as an Orthodontic Consultant. He has served as a consultant to the American Board of Pediatric Dentistry. He has been invited to lecture at numerous professional organizations in national and international meetings, including the United States, Canada and Austria. Among his honors, he was nominated Distinguished University Faculty by the Ohio State University and West Virginia University. He was the recipient of the Student Development Award by the American Association for Dental Research and the West Virginia University School of Dentistry.

Professor Stephen Wei is Professor Emeritus of the Faculty of Dentistry of the University of Hong Kong and Former Dean, Faculty of Dentistry and Director of the Prince Philip Dental Hospital from 1989 to 1997. He was first appointed Chair Professor and Head of the Department of Children's Dentistry and Orthodontics at the University of Hong Kong in 1984. He is Editor Emeritus and was the Founding Editor-in-Chief of *Pediatric Dentistry, The Journal of the American Academy of Pediatric Dentistry* (1978 – 1982). Professor Wei has published extensively, including over 60 chapters in books and monographs and more than 200 research and clinical papers and 180 abstracts. He was the President of the International Association for Dental Research (1993 – 1994)