Case Reprot

pISSN 2234-7518 • eISSN 2005-372X
http://dx.doi.org/10.4041/kjod.2014.44.4.203

THE KOREAN JOURNAL of ORTHODONTICS
KJO

Treatment and retention of relapsed anterior open-bite with low tongue posture and tongue-tie: A 10-year follow-up

Yu-Jin Seo[a]
Su-Jung Kim[a]
Janchivdorj Munkhshur[a]
Kyu-Rhim Chung[b]
Peter Ngan[c]
Seong-Hun Kim[a]

[a]Department of Orthodontics, School of Dentistry, Kyunghee University, Seoul, Korea
[b]Department of Orthodontics, School of Medicine, Ajou University, Suwon, Korea
[c]Department of Orthodontics, School of Dentistry, West Virginia University, Morgantown, WV, USA

The purpose of the current report is to present 6-year long-term stability and 10-year follow-up data for an adult patient who was treated with a tongue elevator for relapsed anterior open-bite. The 19-year-old male patient presented with the chief complaint of difficulty in chewing his food. Collectively, clinical and radiographic examinations revealed an anterior open-bite, low tongue posture, and tongue-tie. The patient opted for orthodontic treatment alone, without any surgical procedure. A lingual frenectomy was recommended to avoid the risk of relapse, but the patient declined because he was not experiencing tongue discomfort. Initial treatment of the anterior open-bite with molar intrusion and tongue exercises was successful, but relapse occurred during the retention period. A tongue elevator was used for retreatment, because the approach was minimally invasive and suited the patient's requirements regarding discomfort, cost, and time. The appliance changed the tongue posture and generated an altered tongue force, which ultimately resulted in intrusive dentoalveolar effects, and a subsequent counterclockwise rotation of the mandible. The results showed long-term stability and were maintained for six years through continual use of the tongue elevator. The results of this case indicated that a tongue elevator could be used not only as an alternative treatment for open-bite, but also as an active retainer.
[Korean J Orthod 2014;44(4):203-216]

Key words: Open-bite, Tongue elevator, Relapse, Retention

Received March 28, 2014; Revised May 7, 2014; Accepted May 12, 2014.

Corresponding author: Seong-Hun Kim.
Professor, Department of Orthodontics, School of Dentistry, Kyunghee University, 26 Kyungheedae-ro, Dongdaemun-gu, Seoul 130-701, Korea.
Tel +82-2-958-9392 **e-mail** bravortho@catholic.ac.kr

The authors report no commercial, proprietary, or financial interest in the products or companies described in this article.

© 2014 The Korean Association of Orthodontists.

This is an Open Access article distributed under the terms of the Creative Commons Attribution Non-Commercial License (http://creativecommons.org/licenses/by-nc/3.0) which permits unrestricted non-commercial use, distribution, and reproduction in any medium, provided the original work is properly cited.

INTRODUCTION

Soft tissue pressure is a factor that influences craniofacial growth and development patterns.[1,2] Further, prior reports have indicated that a correlation exists between tongue position and malocclusion.[3,4] A low tongue posture or tongue-thrusting habit can produce an anterior open-bite and mandibular prognathism. Moreover, abnormal tongue position and functioning are reported to cause relapses after treatment for anterior open-bite, and are potential risk factors for long-term stability.[5,6]

A relapse of anterior open-bite during the retention period is common, and clinicians often face the challenge of retaining treatment results, or retreating a relapsed open-bite. To date, various retention protocols have been suggested for preventing relapses caused by low tongue posture and tongue-tie. Reports have indicated the success of the tongue crib appliance in treating an anterior open-bite malocclusion in young patients with a tongue thrusting habit.[7-9] Likewise, tongue reduction has been effective in preserving treatment results in patients with macroglossia.[10-12] Orofacial myofunctional therapy has also been effective in maintaining closure of anterior open-bite malocclusions that result from changes in tongue position and functioning patterns.[13,14] Conversely, no consensus exists regarding the indications, timing, or method of surgical repair of tongue-tie anomalies.[3,15-18] A lingual frenectomy is usually recommended in cases of tongue-tie, but surgical intervention is not always justified, especially in cases in which the patient has no specific complaints of discomfort.[18]

Herein, we present findings from the 10-year follow-up of a patient who was retreated for a relapsed anterior open-bite without surgical intervention. Treatment of the patient with molar intrusion using temporary skeletal anchorage was initially successful, but the anterior open-bite reoccurred during the retention period due to a persistent low tongue posture. A tongue elevator was subsequently applied as an active retreatment alternative, and was used thereafter as a retainer. The result was successful bite closure and long-term stability. Accordingly, the purpose of this report is to suggest the use of a tongue elevator as a treatment or retention alternative for anterior open-bite.

A tongue elevator is a removable appliance comprising an acrylic base, occlusal rests, and several retentive elements (Figure 1). The acrylic base occupies the entire sublingual space, except for the lingual frenum, and the occlusal rests are placed in the lingual occlusal grooves of the posterior teeth. For retention, a labial bow and other retentive clasps can be added.

The function of the tongue elevator is to keep the

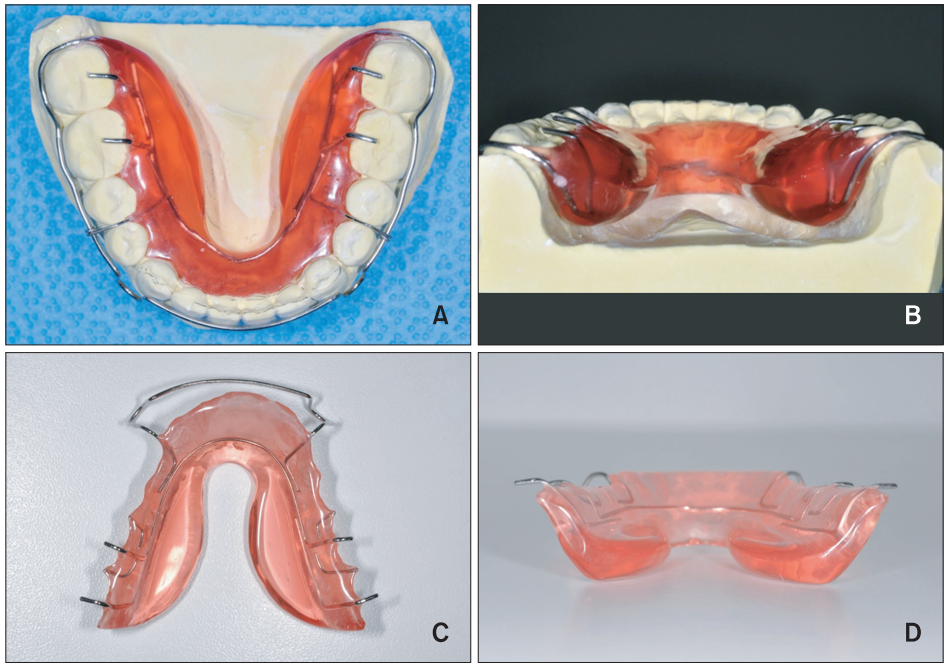

Figure 1. Design of the tongue elevator. Occlusal view (**A**) and lingual view (**B**) of a conventional tongue elevator. The acrylic base occupies the entire mouth floor except for the region that can disturb the movement of the lingual frenum. The occlusal rests are placed on the lingual occlusal grooves of the posterior teeth. In a modified tongue elevator (**C** and **D**), the volume and height of the resin part are reduced for tongue-tie.

http://dx.doi.org/10.4041/kjod.2014.44.4.203

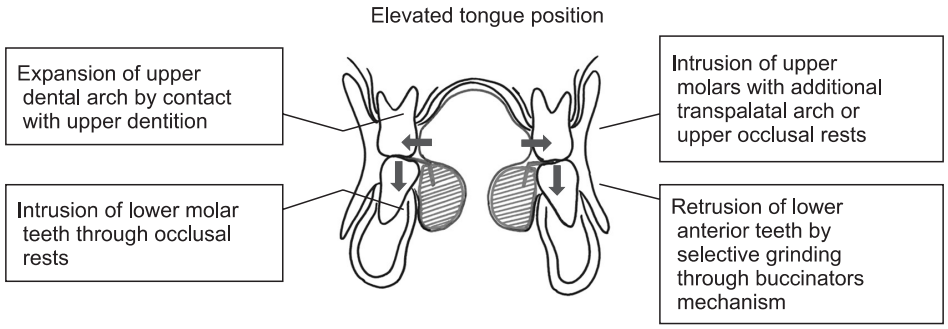

Figure 2. Mechanism of the tongue elevator. Tongue position is elevated after application of the tongue elevator (cross-sectional view). Arrows indicate the pressure generated by altered tongue posture with the tongue elevator.

Figure 3. Pretreatment facial and intraoral photographs.

tongue in a higher than usual position, which is accomplished by the sheer volume of the acrylic base. The positional change induced by the tongue elevator brings about three dentoalveolar effects (Figure 2).[19,20] First, the tongue tends to go back to its original position when elevated, which generates a downward force. This force is then transmitted to the occlusal rests of the appliance, which results in intrusion of the lower posterior teeth. Second, when elevated, the tongue occupies the space under the palatal vault, and contacts the upper dentition. In this position, the tongue exerts an outward force that results in upper arch expansion. Finally, the pushing force exerted by the elevated tongue can be used in conjunction with a transpalatal arch, or upper removable retainer with occlusal rests, to intrude the upper posterior teeth. Thus, the anterior open-bite can be corrected by inhibition of posterior alveolar growth.

The tongue elevator was first described by Chung[19] as a mechanism to correct cases of low tongue posture with anterior open-bite. Subsequently, the effectiveness of the tongue elevator was reported by Kim et al.,[20] who demonstrated the improvement of open-bite in patients with low tongue posture.

The amount of tongue elevation required for each treatment is determined by clinician experience. In cases of tongue-tie, the volume and height of the resin component of the appliance should be reduced, because excessive tension is generated in these patients compared to normal patients with an equal degree of tongue elevation (Figure 1C and 1D). The modified form of the appliance, when used in patients with tongue-tie, produces the appropriate amount of tongue elevation

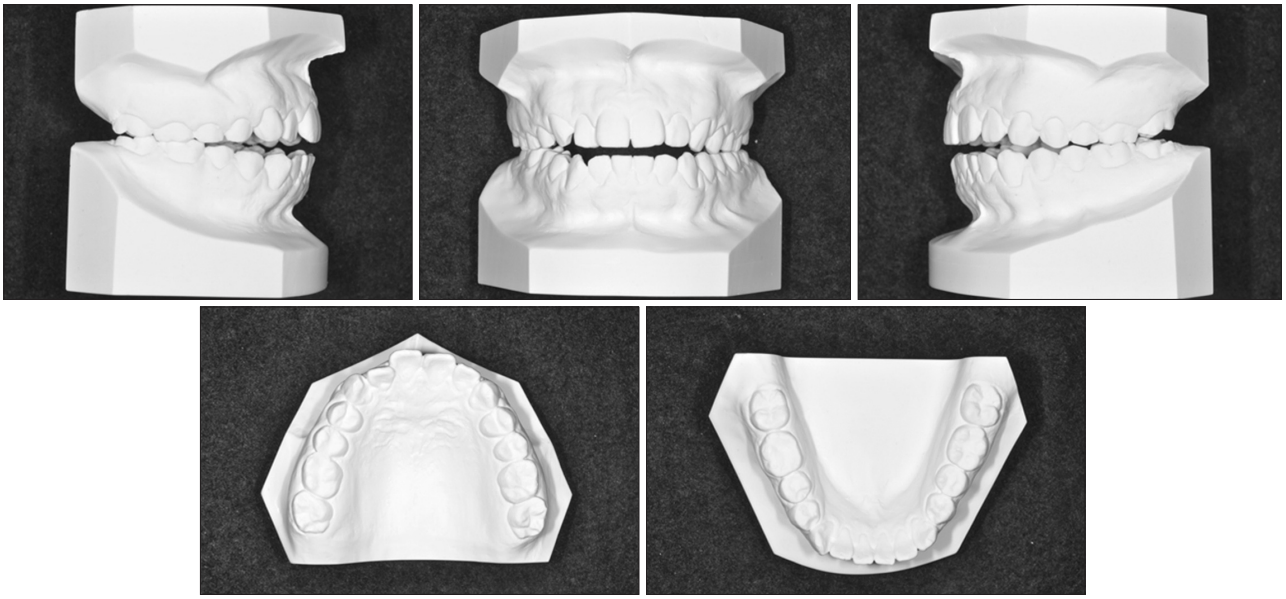

Figure 4. Pretreatment dental casts.

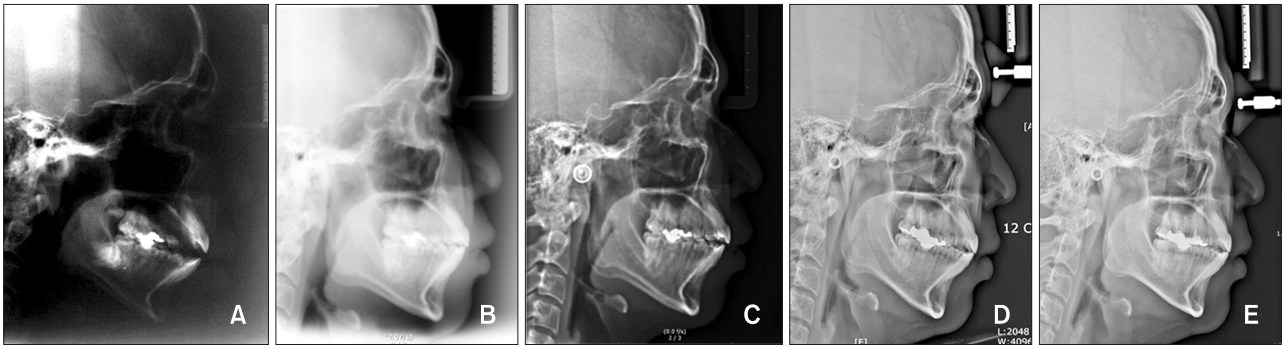

Figure 5. Lateral cephalograms. From the left, initial (A); post-treatment (B); 3-year post-treatment showing relapse tendency (C); 8-year follow-up with 4-year application of tongue elevator (D); and 10-year follow-up with 6-year application of tongue elevator, indicating correction of anterior open-bite and good stability (E).

and tension, and results in comfort to the patient.

After wearing the appliance in the lower arch, the patient was asked to perform tongue movements in all directions. He was instructed to swallow with the upper and lower teeth occluded, and the lips in contact. As well, the application of thumb pressure under the chin proved helpful. This exercise was integral in achieving the proper effects of the appliance, and in avoiding any undesirable iatrogenic tongue thrust.

DIAGNOSIS AND ETIOLOGY

A 19-year-old male patient presented with the chief complaint of difficulty in chewing his food. Clinical examination revealed a retrusive chin, incompetent lips, open-bite, Class III molar relationship, and a negative anterior overbite with shallow overjet (Figures 3 and 4). A minimal amount of crowding was observed and, although the tongue was normal in size, it was positioned low and had tongue-tie (Figures 3 to 5). The patient did not complain of any discomfort or difficulty in function or pronunciation. Lateral cephalometric analysis revealed a Class II skeletal relationship and hyperdivergent pattern (ANB = 5.9°, FMA = 31°; Table 1 and Figure 5A). No indications or symptoms of respiratory disturbances were apparent, and there were no pathologic findings in the temporomandibular joint area.

TREATMENT OBJECTIVES

The treatment goals were to (1) correct the open-bite, (2) improve facial esthetics, and (3) improve the tongue posture for stability.

Table 1. Lateral cephalometric analysis

	Pretreatment	Posttreatment	3-Year posttreatment*	8-Year follow-up†	10-Year follow-up‡
Skeletal					
ANB (°)	5.9	4.9	5.4	5.0	5.0
SNA (°)	84.0	84.0	84.0	84.0	84.0
SNB (°)	78.0	79.5	78.5	79.0	79.0
Pog to N-Perp (mm)	−11.5	−9.0	−11.0	−9.5	−9.5
FMA (°)	31.0	28.0	29.5	28.7	28.7
Dental					
U1-FH (°)	113.0	112.0	112.0	112.0	112.0
L1-MP (IMPA) (°)	101.5	100.0	100.0	100.0	100.0
OB (mm)	−4.0	1.5	−1.0	0.5	0.7
OJ (mm)	2.0	2.0	2.5	1 .5	1 .5
U1-PP (mm)	30.5	31.5	31.5	31.5	31.5
U6-PP (mm)	27.6	26.5	27.4	26.7	26.7
L1-MP (mm)	41.0	42.0	42.0	42.0	42.2
L6-MP (mm)	34.5	33.6	34.4	33.6	33.6
Tongue					
Mean TPD (mm)	10.3	3.4	8.9	3.6	3.3

*Relapse; †4-year application of tongue elevator; ‡6-year application of tongue elevator.

ANB, A point-nasion-B point angle; SNA, sella-nasion-A point angle; SNB, sella-nasion-B point angle; Pog to N-Perp, distance of pogonion to the nasion-perpendicular line to Frankfurt horizontal plane; FMA, Frankfurt horizontal plane-mandibular plane angle; U1-FH, upper incisor-Frankfurt horizontal plane angle; L1-MP (IMPA), lower incisor-mandibular plane angle; OB, overbite; OJ, overjet; U1-PP, perpendicular distance of the maxillary incisor tip to the palatal plane; U6-PP, perpendicular distance of the mesial cusp tip of the maxillary first molar to the palatal plane; L1-MP, perpendicular distance of the mandibular incisor tip to the mandibular plane; L6-MP, perpendicular distance of the mesial cusp tip of the mandibular first molar to the mandibular plane; TPD, tongue-to-palate distance.

According to Ozbek et al.[21], reference lines were drawn and eight different TPDs from the tongue tip were determined by measuring the distances between the points formed with the lines intersecting the dorsum of the tongue and the palatal curvature.

TREATMENT ALTERNATIVES

Depending on the individual causative factors, various approaches including orthodontic extrusion of anterior teeth, intrusion of posterior teeth, and a combination of orthodontic and orthognathic surgeries can be used to treat anterior open-bite. Orthodontic extrusion of anterior teeth may reduce anterior open-bite; however, it does not cause any skeletal changes. Conversely, the other treatment options are known to induce skeletal effects. Intrusion of posterior teeth, as well as surgical impaction of the posterior maxilla, can result in a counterclockwise rotation of the mandible, closure of the anterior open-bite, and forward and upward displacement of B-point and pogonion. Additionally, the results may improve a retrognathic profile to a Class I skeletal relationship. The difference between the two options is dependent on the dental or skeletal causative factor, the amount of vertical correction, and the risks of the surgical procedure. To attain long-term stability, however, a lingual frenectomy and tongue exercises are also required to minimize the risk factors for relapse.

After discussing the various treatment options and the importance of correct tongue posture, the patient opted to receive only orthodontic treatment, without any surgical procedure. In order to correct the anterior open-bite, plans were made to intrude the upper and lower posterior teeth with the aid of temporary skeletal anchorage. The patient opted not to have a lingual frenectomy, as he felt no tongue discomfort. Instead, he promised to comply with the tongue exercises, acknowledging the potential for relapse if the exercises were not performed.

TREATMENT PROGRESS

Four C-tube plates (Jin Biomed Co., Bucheon, Korea) were installed with mini-screws (4 mm in length and 1.5 mm in diameter, Jin Biomed Co.), at the zygomatic buttress in the maxilla and the mandibular posterior buccal cortical bone between the first molar and second molar (Figure 6). A transpalatal arch and lingual arch were incorporated in the upper and lower dentition, respectively, to maintain the torque of the first molar and the intermolar width. The patient was reminded of the importance of tongue position during treatment, and was instructed to swallow in a manner that forced the tongue to contact the palatal surface. After four months, during which time contact of the opposing premolars was established, the fixed orthodontic appliance was combined with further molar intrusion and Class III elastics, to achieve an appropriate overbite and overjet, as well as better interdigitation.

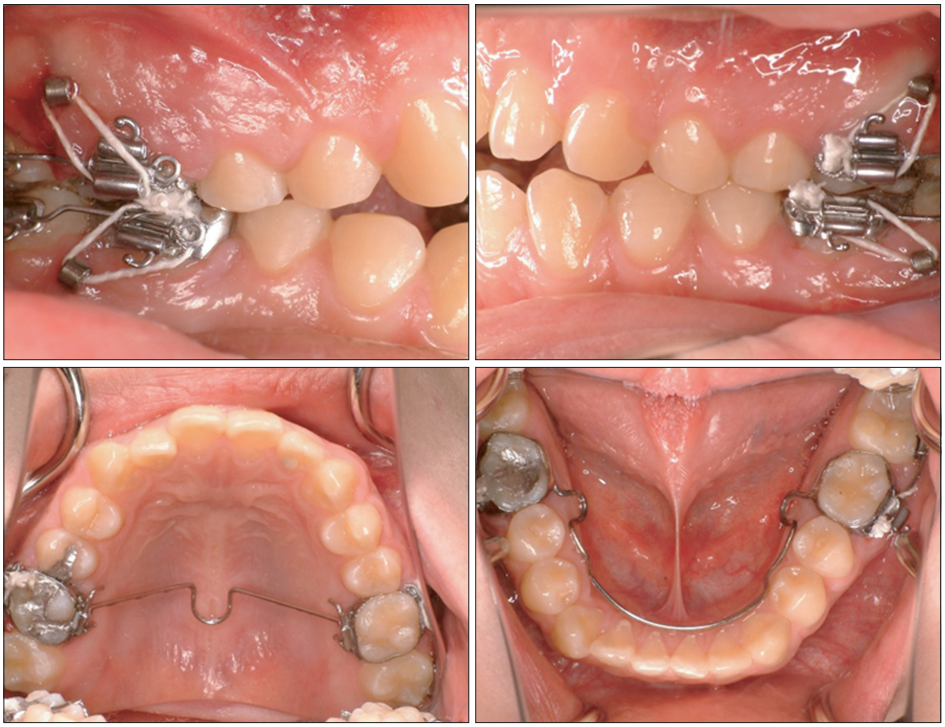

Figure 6. Initial treatment mechanics for molar intrusion. Four C-tubes installed in the each posterior area with a transpalatal arch in the upper dentition, and a lingual arch in the lower arch.

http://dx.doi.org/10.4041/kjod.2014.44.4.203



Figure 7. Post-treatment facial and intraoral photographs.



Figure 8. Post-treatment dental casts.

Figure 14. Facial and intraoral photographs at 10-year follow-up with 6-year application of tongue elevator.

Figure 15. Dental casts at 10-year follow-up with 6-year application of tongue elevator.

http://dx.doi.org/10.4041/kjod.2014.44.4.203

servative approaches in the treatment of abnormal tongue positions include habit appliances such as a tongue crib or spur. Prior reports have indicated that use of a tongue crib corrected open-bite in young patients, and changed the tongue position and functioning patterns.[7-9] However, these appliances are indicated in cases of abnormal tongue posture with tongue thrust, but not with tongue-tie. Moreover, such appliances cannot utilize the tongue force to intrude the molars.

In order to correct a low tongue posture with tongue-tie, and to utilize the tongue as an active treatment method, tongue elevation and the force generated from the elevated tongue should be considered. A tongue elevator is a unique appliance that can correct the tongue position and intrude molars simultaneously (Figures 1, 2, and 12).[19,20] The advantages of the tongue elevator are attributed to its ability to utilize the tongue force that results from correcting the tongue posture. An elevated tongue position generates forces and provides vertical control of the mandibular molars, as well as vertical and transverse support of maxillary molars. In addition, tongue exercises can be performed at the elevated position.

In the current case, the tongue was normal in size and function despite the presence of tongue-tie. Nonetheless, the patient was reluctant to undergo corrective surgery. Therefore, instead of retreatment with fixed orthodontic appliances, a modified tongue elevator was applied as an active retainer to correct the low tongue posture resulting from tongue-tie (Figures 1 and 12). Since the elevated tongue tends to move downward, a downward force was transmitted on the lower molars through the occlusal rests in the tongue elevator. Further, the elevated tongue supported the upper molars in the same manner. After three months of using the tongue elevator, the open-bite was closed with intrusion of the mandibular and maxillary molars and counterclockwise rotation of the mandible. Additionally, the corrective conditions were successfully retained for six years following the initial use of the tongue elevator.

This report describes the 10-year follow-up and 6-year long-term stability of an adult male patient treated with a tongue elevator for relapsed anterior open-bite, in which retreatment with the tongue elevator successfully reversed initial treatment relapse. The results of this case suggest the possible use of a tongue elevator appliance as a conservative method for the nonsurgical treatment of anterior open-bite with tongue-tie, and for the long-term maintenance of treatment results. Nonetheless, despite the promising results, a lack of standardized and quantified diagnostic tools for tongue abnormalities exists. Therefore, a prospective study should be developed to enable precise diagnosis of the tongue, and to evaluate the forces generated in various tongue positions.

CONCLUSION

The current report presents the details of a 10-year follow-up of a patient who was retreated for a relapsed anterior open-bite without surgical intervention. Treatment of the patient with molar intrusion using temporary skeletal anchorage was initially successful, but the anterior open-bite reoccurred during the retention period due to a persistent low tongue posture. A tongue elevator was subsequently applied as an active retreatment alternative, and was used thereafter as a retainer. The application of the tongue elevator resulted in intrusive dentoalveolar effects, and counterclockwise rotation of the mandible. Treatment results were maintained for six years, which indicated long-term stability. In conclusion, a tongue elevator could be an effective alternative for treatment of open-bite, not only as an active retainer, but also as a viable treatment method.

REFERENCES

1. Proffit WR. Equilibrium theory revisited: factors influencing position of the teeth. Angle Orthod 1978; 48:175-86.
2. Proffit WR. On the aetiology of malocclusion. The Northcroft lecture, 1985 presented to the British Society for the Study of Orthodontics, Oxford, April 18, 1985. Br J Orthod 1986;13:1-11.
3. Horton CE, Crawford HH, Adamson JE, Ashbell TS. Tongue-tie. Cleft Palate J 1969;6:8-23.
4. Proffit WR, Mason RM. Myofunctional therapy for tongue-thrusting: background and recommendations. J Am Dent Assoc 1975;90:403-11.
5. Yamaguchi H, Sueishi K. Malocclusion associated with abnormal posture. Bull Tokyo Dent Coll 2003; 44:43-54.
6. Tsuiki S, Handa S, Ohyama K. A simple method for evaluation of tongue position. J Oral Rehabil 2007; 34:304-10.
7. Huang GJ, Justus R, Kennedy DB, Kokich VG. Stability of anterior openbite treated with crib therapy. Angle Orthod 1990;60:17-24; discussion 25-6.
8. de Cuebas JO. Nonsurgical treatment of a skeletal vertical discrepancy with a significant open bite. Am J Orthod Dentofacial Orthop 1997;112:124-31.
9. Taslan S, Biren S, Ceylanoglu C. Tongue pressure changes before, during and after crib appliance therapy. Angle Orthod 2010;80:533-9.
10. Hotokezaka H, Matsuo T, Nakagawa M, Mizuno A, Kobayashi K. Severe dental open bite malocclusion with tongue reduction after orthodontic treatment. Angle Orthod 2001;71:228-36.

11. Liu ZJ, Shcherbatyy V, Gu G, Perkins JA. Effects of tongue volume reduction on craniofacial growth: A longitudinal study on orofacial skeletons and dental arches. Arch Oral Biol 2008;53:991-1001.
12. Chatzistavrou E, Kolokitha OE, Topouzelis N. A severe open bite case treated with orthodontics and tongue reduction surgery: 13-year followup. A case report. Aust Orthod J 2012;28:94-103.
13. Takahashi O, Iwasawa T, Takahashi M. Integrating orthodontics and oral myofunctional therapy for patients with oral myofunctional disorders. Int J Orofacial Myology 1995;21:66-72.
14. Smithpeter J, Covell D Jr. Relapse of anterior open bites treated with orthodontic appliances with and without orofacial myofunctional therapy. Am J Orthod Dentofacial Orthop 2010;137:605-14.
15. Messner AH, Lalakea ML. Ankyloglossia: controversies in management. Int J Pediatr Otorhinolaryngol 2000;54:123-31.
16. García Pola MJ, González García M, García Martín JM, Gallas M, Seoane Lestón J. A study of pathology associated with short lingual frenum. ASDC J Dent Child 2002;69:59-62, 12.
17. Ruffoli R, Giambelluca MA, Scavuzzo MC, Bonfigli D, Cristofani R, Gabriele M, et al. Ankyloglossia: a morphofunctional investigation in children. Oral Dis 2005;11:170-4.
18. Suter VG, Bornstein MM. Ankyloglossia: facts and myths in diagnosis and treatment. J Periodontol 2009;80:1204-19.
19. Chung KR. Clinical dental orthodontics. Seoul, Korea: Myung Moon Pub Co; 1998.
20. Kim YS, Kown SY, Park YG, Chung KR. Clinical application of the tongue elevator. J Clin Orthod 2002; 36:104-6.
21. Ozbek MM, Memikoglu UT, Altug-Atac AT, Lowe AA. Stability of maxillary expansion and tongue posture. Angle Orthod 2009;79:214-20.
22. Lopez-Gavito G, Wallen TR, Little RM, Joondeph DR. Anterior open-bite malocclusion: a longitudinal 10-year postretention evaluation of orthodontically treated patients. Am J Orthod 1985;87:175-86.
23. Lentini-Oliveira D, Carvalho FR, Qingsong Y, Junjie L, Saconato H, Machado MA, et al. Orthodontic and orthopaedic treatment for anterior open bite in children. Cochrane Database Syst Rev 2007;(2): CD005515.
24. Greenlee GM, Huang GJ, Chen SS, Chen J, Koepsell T, Hujoel P. Stability of treatment for anterior openbite malocclusion: a meta-analysis. Am J Orthod Dentofacial Orthop 2011;139:154-69.
25. Tanaka E, Yamano E, Inubushi T, Kuroda S. Management of acquired open bite associated with temporomandibular joint osteoarthritis using miniscrew anchorage. Korean J Orthod 2012;42:144-54.
26. Sugawara J, Baik UB, Umemori M, Takahashi I, Nagasaka H, Kawamura H, et al. Treatment and posttreatment dentoalveolar changes following intrusion of mandibular molars with application of a skeletal anchorage system (SAS) for open bite correction. Int J Adult Orthodon Orthognath Surg 2002;17:243-53.
27. Baek MS, Choi YJ, Yu HS, Lee KJ, Kwak J, Park YC. Long-term stability of anterior open-bite treatment by intrusion of maxillary posterior teeth. Am J Orthod Dentofacial Orthop 2010;138:396. e1-9; discussion 396-8.
28. Volk J, Kadivec M, Mušič MM, Ovsenik M. Three-dimensional ultrasound diagnostics of tongue posture in children with unilateral posterior crossbite. Am J Orthod Dentofacial Orthop 2010;138:608-12.
29. Iwasaki T, Saitoh I, Takemoto Y, Inada E, Kakuno E, Kanomi R, et al. Tongue posture improvement and pharyngeal airway enlargement as secondary effects of rapid maxillary expansion: a cone-beam computed tomography study. Am J Orthod Dentofacial Orthop 2013;143:235-45.
30. Hohoff A, Ehmer U. Effects of the Castillo-Morales stimulating plate on speech development of children with Down's syndrome. A retrospective study. J Orofac Orthop 1997;58:330-9.