EARLY CLASS III TREATMENT: IS THE BENEFIT WORTH THE BURDEN?

Peter Ngan

The objective of early orthodontic treatment is to create a more favorable environment for future dentofacial development. Early Class III treatment, such as correction of anterior crossbite or normalization of the jaw positions, can prevent progressive and irreversible soft-tissue or bony changes, reduce the amount of dental compensation to skeletal discrepancy that often is associated with a more severe malocclusion in late adolescence, prevent abnormal incisal wear, improve lower lip posture and generally improve the psychosocial well-being of the child (Joondeph, 1993). However, success in early Class III treatment depends on accurate diagnosis of the underlying skeletal and dentoalveolar problems and on anticipating the probable growth changes. Class III malocclusion may be made up of different combinations of skeletal and dentoalveolar components. Consideration of the various components is essential to understanding the underlying causes of the discrepancy which, in turn, is essential to choosing the appropriate treatment.

According to Guyer and colleagues (1986), the most frequent Class III pattern is a normal maxilla and prognathic mandible. Approximately 25% of Class III patients in their study had a deficiency in the maxilla and 57% of patients with either a normal or prognathic mandible had a deficiency in the maxilla. Protraction facemask therapy has been successful in the early treatment of Class III patients with maxillary deficiencies (McNamara, 1987; Turley, 1988; Ngan *et al.*, 1992). However, 25% to 33% of the treated patients reverted to an anterior crossbite when they underwent their pubertal growth spurt (Ngan *et al.*, 1997; Hägg *et al.*, 2003; Westwood *et al.*, 2003). These studies also found very few morphological differences at the start of treatment between patients who were successfully camouflaged by orthodontic treatment and those who eventually needed surgical intervention. Turpin (1981) suggests that early treatment will be more successful in patients who have a convergent facial type with an anteroposterior functional shift, symmetrical condyle growth, mild skeletal disharmony, and who are pre-pubescent. There is a need for a diagnostic scheme that will differentiate patients whose malocclusions can be successfully camouflaged with orthodontic treatment from those who eventually will need surgical intervention.

Clinicians often are reluctant to engage in early orthopedic treatment in Class III patients because it is difficult to predict excessive mandibular growth (Ngan, 2002). Thompson (1994) commented on the individuality of the facial skeleton and concluded that growth cannot be predicted because patient growth spurts can occur anytime before, during or after orthodontic treatment. Patients who receive early orthodontic or orthopedic treatment can end up needing surgery at the end of the growth period. The ability to predict mandibular growth early in life can help clinicians decide whether early orthodontic treatment or post-pubertal surgery is the most efficacious treatment. The objective of this chapter is to outline the strategy for differentiating pseudo and true Class III malocclusions and to discuss tools that can be used to predict future growth changes.

DIFFERENTIAL DIAGNOSIS OF CLASS III MALOCCLUSION

Familial History of Class III Malocclusion

The few studies of human inheritance and its role in the Class III malocclusion support the belief that the growth and size of the mandible are affected by heredity. The most famous study of inheritance, as described by McGuigan (1966), is that of the Hapsburg family. Of the 40 family members for whom records were available, 33 had prognathic mandibles. Litton studied the families of 51 individuals who had Class III anomalies and concluded that Class III characteristics were related to genetic inheritance for both offspring and siblings (Litton *et al.*, 1970). It is recommended, therefore, that a patient's record should include information on family members who have Class III malocclusions. In addition, a lateral cephalogram should be taken of such family members, if possible, to determine whether their Class III malocclusions have a maxillary deficiency component, a mandibular excess component or a combination of both.

Dental Assessment

In the mixed dentition, patients with Class III malocclusions may present with a flush terminal plane or mesial terminal plane together with retroclined mandibular incisors. Patients with a mesial step of 2 mm or more can have a 19% chance of developing a Class III permanent molar relationship (Bishara *et al.*, 1988). In the permanent dentition, a full-step Class III molar relationship usually has a worse prognosis than a half-step

Class III molar relationship. The Class III molar relationship also can be accompanied by a negative overjet. If a positive overjet or end-to-end incisal relationship is present together with retroclined mandibular incisors, one should suspect a compensated Class III malocclusion. If a negative overjet is present, a functional assessment should be undertaken.

Functional Assessment

To determine whether a centric relation/centric occlusion (CO/CR) discrepancy exists, the relationship of the maxilla to the mandible must be evaluated. Anterior positioning of the mandible may result from abnormal tooth contact that forces the mandible forward. Patients who present with a forward shift of the mandible on closure may have a Class I skeletal pattern, a normal facial profile, and Class I molar relationship in centric relation. This condition is referred to as a pseudo Class III malocclusion. Elimination of the CO/CR discrepancy or correction of the anterior crossbite should reveal whether the condition is a simple Class I malocclusion or a true Class III malocclusion.

Profile Assessment

The lateral profile of patients in repose and smiling can provide valuable information in diagnosing a Class III malocclusion. A straight or concave facial profile and mandibular prognathism in a young patient indicate that there is an underlying skeletal malocclusion. When examining the lateral profile of a patient in a repose position, an imaginary line is dropped down from the middle of the forehead to evaluate the midface and the chin position. In young children, the anatomical landmark 'subnasale' usually is 1 to 2 mm ahead of this imaginary line, and the chin position usually is behind this line. When examining the lateral profile of a young, smiling patient, the maxillary central incisors should be close to or touching the imaginary line from the forehead. The presence of a midface deficiency would be indicated if the incisors are behind the imaginary line and the patient's tissue contour is straight or concave.

Cephalometric Assessment

When compared to subjects with normal skeletal patterns, Class III patients have a shorter anterior cranial base, a more obtuse gonial angle, the glenoid fossa is positioned further forward, the maxillary incisors are more proclined and the mandibular incisors are more retroclined (Ngan *et al.*, 1996). However, there are very few cephalometric studies that compare pseudo Class III patients with true skeletal Class III patients. One study

comparing the cephalometric measurements of pseudo Class III patients and true skeletal Class III patients with Class I patients revealed that most of the measurements for pseudo Class III patients fell between those for true skeletal Class III and Class I individuals (Li and Lin, 1987). The only measurement with diagnostic value for differentiating pseudo Class III patients from true skeletal Class III patients was the gonial angle. The average gonial angle of pseudo Class III patients was lower (120°) than that for both Class I (122°) and true skeletal Class III (124°) patients. Discriminant analysis found the WITS analysis to be most decisive in distinguishing the need for camouflage treatment from the need for surgical treatment (Stellzig-Eisenhauer *et al.*, 2002). The average WITS for the non-surgery group was -4.6 mm $\pm$ 1.7 mm and -12.2 mm $\pm$ 4.3 mm for the surgery group.

Growth Prediction of Class III Malocclusion

No two persons are identical, and each person has a unique facial growth pattern. Thompson (1994) commented on the uniqueness of individual facial growth and concluded that growth cannot be predicted because maximum growth can occur before, during or after orthodontic treatment. However, poor skeletal patterns tend to stay the same or become worse, and excellent skeletal patterns tend to stay the same or get better, and grow over a longer time span. This observation was corroborated by studies that followed patients into their pubertal growth spurt (Ngan *et al.*, 1997; Hägg *et al.*, 2003; Westwood *et al.*, 2003). Patients with excess mandibular growth continued to get worse during the pubertal growth period and patients with mild to moderate Class III growth were eventually able to camouflage it with orthodontic treatment.

Several investigations have attempted to predict the progression of Class III malocclusion. Björk and Skieller (1983) used a single cephalogram to identify seven structural signs of extreme mandibular growth rotation occurring during growth. The seven signs are related to the inclination of the condylar head, the curvature of the mandibular canal, the shape of the lower border of the mandible, the width of the symphysis, the interincisal angle, the intermolar angle, and the anterior lower face height. Discriminant analysis of long-term results of early treatment identified several variables that had predictive value. Franchi and colleagues (1997) found that the inclination of the condylar head, the maxillomandibular vertical relationship together with the width of the mandibular arch could predict success or failure for early Class III treatment. Ghiz and Ngan (2001) found that the position of the mandi-

ble, the ramal length, the corpus length, and the gonial angle could be used to predict successful outcomes with 95% accuracy. However, this method can predict unsuccessful outcomes with only 70% accuracy.

The use of serial radiographs and a growth treatment response vector (GTRV) analysis to predict excessive mandibular growth is more specific to the individual's growth rate and direction. Using this method, the horizontal growth changes of the maxilla and the mandible, which occur during the time period between when the pre-treatment radiograph is taken and when the follow-up radiograph is taken, can be determined by locating the Point A and Point B on the first radiograph. The occlusal plane (O) is constructed by using the mesial buccal cusp of the maxillary molars and the incisal tip of the maxillary incisors as landmarks. The lines AO and BO then are constructed by connecting Point A and Point B perpendicular to the occlusal plane.

The first tracing is superimposed on the follow-up radiograph using the stable landmarks on the midsagittal cranial structure. Point A and Point B on the follow-up radiograph are located and the lines AO and BO the are constructed by connecting Points A and B of the follow-up radiograph to the occlusal plane of the first tracing. The distance between Point A of the two tracings along the occlusal plane represents the growth changes of the maxilla, and the distance on the occlusal plane of Point B represents the growth changes of the mandible. The GTRV ratio is calculated by using the following formula:

$$\text{GTRV} = \frac{\text{Horizontal growth changes of the maxilla}}{\text{Horizontal growth changes of the mandible}}$$

In a study in which patients were treated with a protraction facemask, the patients were divided into two groups of 20 each (Ngan and Wei, 2004). The first group was comprised of patients who were treated successfully with the protraction headgear based on the follow-up radiograph and the second group was comprised of patients who were treated unsuccessfully with the protraction headgear. Significant differences were found between the GTRV ratios for the two treatment groups ($p < 0.05$). The mean GTRV ratio for the successful group was 0.49 ± 0.14 with a range of 0.33 to 0.88. The mean GTRV ratio for the unsuccessful group was 0.22 ± 0.10 with a range of 0.06 to 0.38.

CASE REPORT

A typical case is illustrated here to demonstrate the use of GTRV ratio to predict excessive mandibular growth. A 10-year-old Chinese girl

presented with a skeletal Class III malocclusion and a flat facial profile (Fig. 1). Clinical examination revealed an anterior crossbite with Class III molar and canine relationships. The inclination of her maxillary incisors was within the normal range, but her mandibular incisors were retroclined. The cephalometric radiograph revealed a deficient maxilla and a normal mandible with a WITS appraisal of -3.0 mm (Fig. 2).

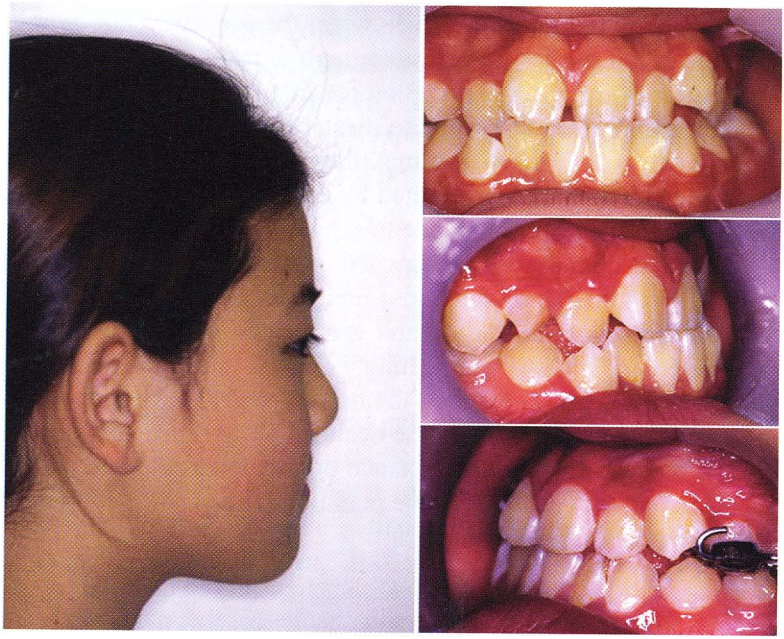

Figure 1. A 10-year-old Chinese girl with a flat facial profile, an anterior crossbite and crowding of the upper and lower dentitions.

The patient was treated with a maxillary expansion appliance together with a protraction facemask for eight months. A positive overjet was established after eight months of treatment (Fig. 3). Superimposition of the pre- and post-treatment radiographs revealed primarily a downward growth of the maxilla (Fig. 4). The patient was followed for three years until the age of 13 years at which time a decision regarding treatment choices was necessary. Should the patient begin Phase II orthodontic treatment to camouflage the malocclusion or should she wait until growth was completed and undergo surgery to correct the jaw discrepancy? Figure 5 shows the profile and intraoral photos of the patient at the age of 13 years.

Figure 2. Cephalometric radiograph showing a skeletal Class III malocclusion with increased lower face height.

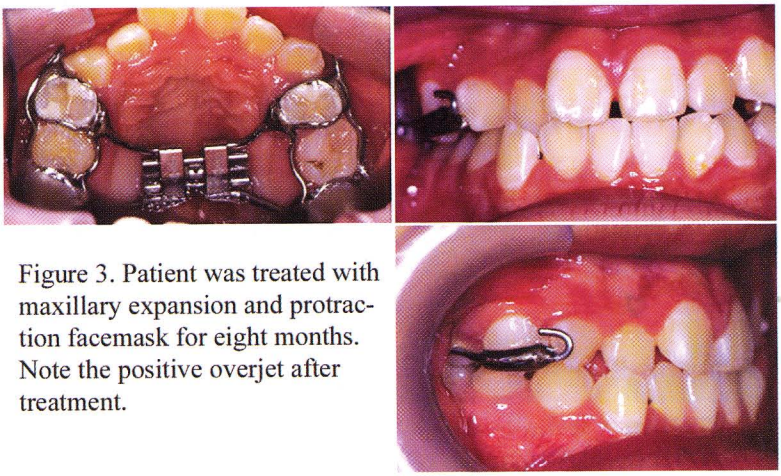

Figure 3. Patient was treated with maxillary expansion and protraction facemask for eight months. Note the positive overjet after treatment.

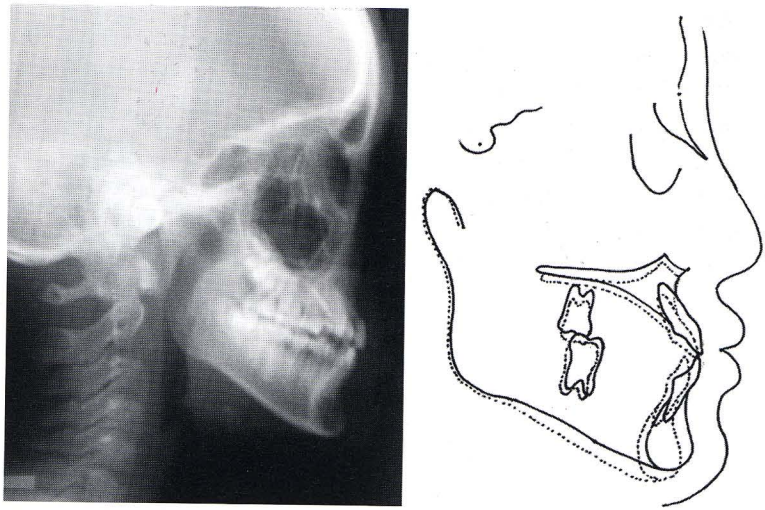

Figure 4. Cephalometric radiograph taken after facemask treatment (*left*). Superimposition showing that correction of the anterior crossbite was due primarily to downward growth of the maxilla and downward and backward rotation of the mandible (*right*).

Figure 5. Two-year post-treatment follow-up record showing changes in the soft tissue profile and molar relationship.

A GTRV analysis was performed using the pre-treatment and follow-up radiographs (Fig. 6). The ratio of 0.8 (norm = 0.77) indicated parallel growth of the maxilla and mandible, and the vectors indicated a forward and downward growth of the maxilla and mandible after face-mask treatment (Fig. 7). The decision was made to camouflage the malocclusion with orthodontic treatment. Figure 8 shows the post-treatment facial and intraoral photos of the 15-year-old patient who has a satisfactory occlusion at the end of treatment.

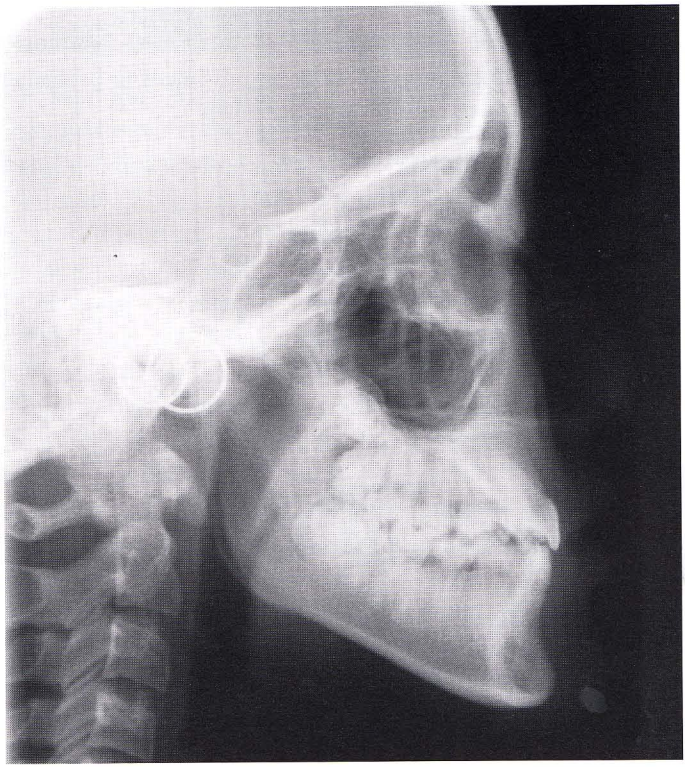

Figure 6. Cephalometric radiograph taken immediately prior to the beginning of Phase II, comprehensive orthodontic treatment to camouflage the skeletal malocclusion.

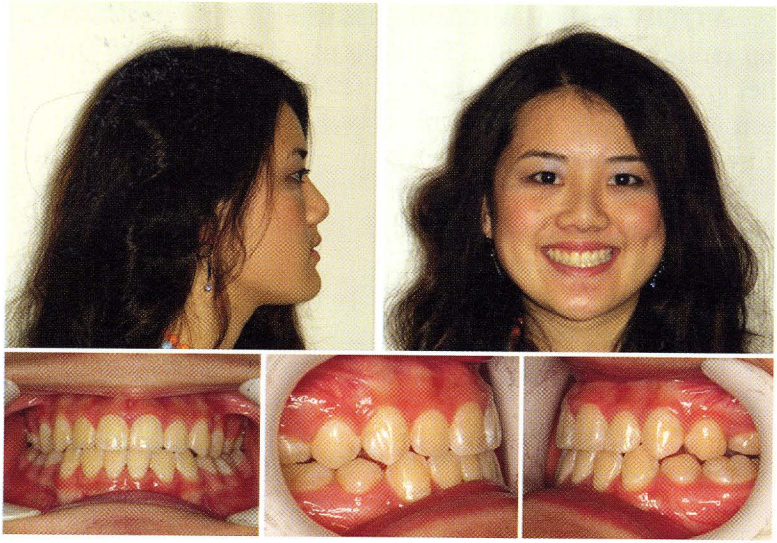

Figure 7. Post-treatment records show improvement in occlusion and facial profile after phase II orthodontic treatment.

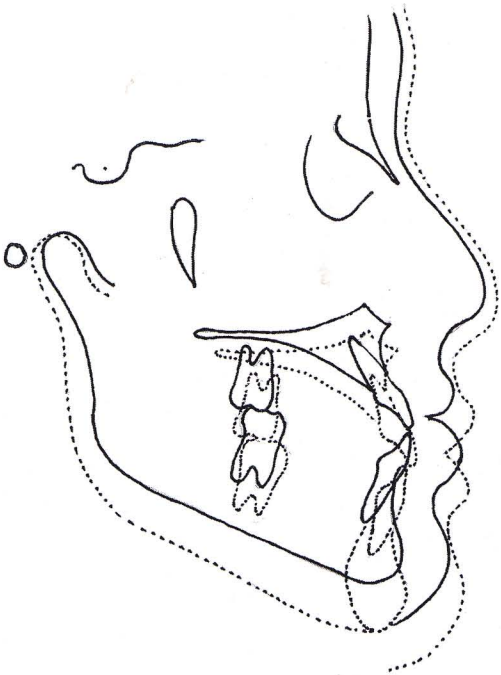

Figure 8. Superimposition showing the growth changes during the two phases of treatment.

CONCLUSIONS

1. Success in early Class III treatment depends on accurate diagnosis of the underlying skeletal and dentoalveolar problems and on anticipating the probable growth changes.

2. Early Class III treatment allows for favorable skeletal response with facemask or chin-cup treatment and improvement in facial profile and self-esteem. In addition, early Class III treatment provides the clinician with an opportunity to observe individual growth rates and direction.

3. The use of serial radiographs and GTRV analysis helps the clinician to decide whether to begin phase II orthodontic treatment during the pubertal growth period or to wait until growth is completed and intervene surgically.

REFERENCES

Bishara SE, Hoppens BJ, Jakobsen Jr, Kohout FJ. Changes in the molar relationship between the primary and permanent dentitions: A longitudinal study. Am J Orthod Dentofacial Orthop 1988;93:19-28.

Björk A, Skieller V. Normal and abnormal growth of the mandible. A synthesis of longitudinal cephalometric implant studies over a period of 25 years. Eur J Orthod 1983;5:1-46.

Franchi L, Baccetti T, Tollaro L. Predictive variables for the outcome of early functional treatment of Class III malocclusion. Am J Orthod Dentofacial Orthop 1997;112:80-86.

Ghiz M, Ngan P. Cephalometric variables to predict future success of early orthopedic Class III treatment. Am J Orthod Dentofacial Orthop 2005;127:301-306.

Guyer EC, Ellis EE, McNamara JA Jr, Behrents RG. Components of Class III malocclusion in juveniles and adolescents. Angle Orthod 1986;56:7-30.

Hägg U, Tse A, Bendeus M, Rabie AB. Long-term follow-up of early treatment with reverse headgear. Eur J Orthod 2003;25:95-102.

Joondeph DR. Early orthodontic treatment. Am J Orthod Dentofacial Orthop 1993;104:199-200

Li KW, Lin JJ. Comparison between pseudo and true Class III malocclusion by Veterans General Hospital cephalometric analysis. Clin Dent 1987;7:69-78.

Litton SF, Ackermann LV, Isaacson RJ, Shapiro BL. A genetic study of Class III malocclusion. Am J Orthod 1970;58:565-577.

McGuigan DG. *The Hapsburgs*. London, WH Allen, 1966.

McNamara JA Jr. An orthopedic approach to the treatment of Class III malocclusion in young patients. J Clin Orthod 1987;21:598-608.

Ngan P. Biomechanics of maxillary expansion and protraction in Class III patients. Am J Orthod Dentofacial Orthop 121:582-583;2002.

Ngan P, Hägg U, Yiu C, Merwin D, Wei SHY. Dentoskeletal and soft tissue profile changes in response to protraction headgear treatment. Am J Orthod Dentofacial Orthop 1996;109:38-49.

Ngan P, Hägg U, Yiu C, Wei SHY. Treatment response and long-term dentofacial adaptations to maxillary expansion and protraction. Semin Orthod 1997;3:255-264.

Ngan P, Wei SHY. Early treatment of Class III patients to improve facial aesthetics and predict future growth. Hong Kong Dent J 2004;1:24-30.

Ngan P, Wei SHY, Hägg U, Yiu CK, Merwin D, Stickel B. Effect of protraction headgear on Class III malocclusion. Quintessence Int 1992;23:197-207.

Stellzig-Eisenhauer A, Lux CJ, Schuster G. Treatment decision in adult patients with Class III malocclusion: Orthodontic therapy or orthognathic surgery? Am J Orthod Dentofacial Orthop 2002;122:27-38.

Thompson JR. The individuality of facial skeletal growth. Part 2 Am J Orthod Dentofacial Orthop 1994;105:224-240.

Turley PK. Orthopedic correction of Class III malocclusion with palatal expansion and custom protraction headgear. J Clin Orthod 1988;22: 314-325.

Turpin DL. Early Class III treatment. Unpublished thesis presented at 81st session, Am Assoc Orthod, San Francisco, 1981.

Westwood PV, McNamara JA Jr, Baccetti T, Franchi L, Sarver DM. Long-term effects of Class III treatment with rapid maxillary expansion and facemask therapy followed by fixed appliances. Am J Orthod Dentofacial Orthop 2003;123:266-278.