Cephalometric A point changes during and after maxillary protraction and expansion

Shiva Shanker, MDS, MS,[a] Peter Ngan, DMD,[b] Dale Wade, DDS, MS,[c] Michael Beck, DDS, MS,[d] Cynthia Yiu, BDS, MS,[e] Urban Hägg, DDS, Odont Dr,[f] and Stephen H. Y. Wei, DDS, MS, MDS,[g]

Morgantown, W.V., Columbus, Ohio, and Hong Kong

The purpose of this study was to analyze the treatment and posttreatment maxillary changes achieved with maxillary protraction therapy. The cephalometric records of 25 consecutively treated Chinese children with Class III malocclusions (mean age 8.4 years) were analyzed for cephalometric A point changes, which were then compared with an untreated, age and sex matched Class III control sample. A cephalometric maxillary superimposition technique was used to differentiate between the skeletal and the local contributions to the total A point change. Results showed that 6 months of maxillary protraction therapy produced a mean A point advancement of 2.4 mm compared with 0.2 mm in the control group. Of this advancement, 75% was found to be due to skeletal maxillary advancement and 25% was attributed to local remodeling. Significantly less downward movement of A point was found with treatment compared with the controls, which could be related to the direction of force application. No significant differences were found in the horizontal and the vertical movements of A point between the treatment and the control groups during the 12-month posttreatment period, indicating stability of early maxillary protraction in patients with Class III malocclusions. (Am J Orthod Dentofac Orthop 1996;110:423-30.)

The dilemma of whether to treat the developing Class III malocclusion early by orthopedic intervention or later by surgical means still lacks a clear consensus. Success of early orthopedic intervention is dependant on the ability to therapeutically modify the growing facial skeleton. Favorable changes have been reported with appliances such as chincup and maxillary protraction appliances.[1-17] An important clinical question, however, is whether it is possible to significantly and permanently alter the genetic growth pattern.[4,7]

Orthopedic maxillary protraction has been increasingly advocated in the treatment of Class III malocclusions, especially those with maxillary retrusion.[1,3,6,8-10,14-25] Several recent studies have shown that maxillary retrusion contributed to a significant number of skeletal Class III malocclusions, either alone or in combination with mandibular protrusion.[26-33]

Several animal studies have shown significant forward displacement of the maxilla, accompanied by histologic changes in the circum-maxillary sutures with orthopedic maxillary protraction therapy.[10-13,34] Clinically, different types of maxillary protraction devices have been reported to be successful in the treatment of the developing Class III malocclusion,[3,6,8-10,14-17,19,21-24] and orthopedic maxillary expansion before protraction has been reported to facilitate maxillary protraction.[14-17] Though several studies have reported on the favorable maxillary changes achieved with maxillary protraction treatment,[3,5,6,9,15-17,23,24] few have reported on the posttreatment changes.[3,5,9,23]

The most common method of evaluating maxillary changes involved a cephalometric estimation of maxillary A point changes, and any change in A point was assumed to represent maxillary skeletal change. Houston[35] discussed the local remodeling changes incident to maxillary incisor movement and its effect on A point. Several studies have reported on the incisal changes that result from maxillary protraction.[6,8,9,16] However, none of these studies have quantified the skeletal and local remodeling contributions to the measured A point change.

Baumrind et al.[36] described a cephalometric maxillary superimposition technique to differentiate between the local remodeling and the skeletal changes that occur in the maxilla. A similar technique described

Based on the thesis submitted by Dr. Shanker in partial fulfillment of the requirements for the Master of Science degree.
[a]Resident, Section of Orthodontics, College of Dentistry, The Ohio State University.
[b]Professor and Chairman, Department of Orthodontics, West Virginia University.
[c]Interim Chairman, Section of Orthodontics, College of Dentistry, The Ohio State University.
[d]Associate Professor, Section of Endodontics, College of Dentistry, The Ohio State University.
[e]Clinical Dental Surgeon, Department of Children's Dentistry and Orthodontics, The University of Hong Kong.
[f]Professor and Head, Department of Children's Dentistry and Orthodontics, The University of Hong Kong.
[g]Professor and Dean, Faculty of Dentistry, The University of Hong Kong.
Reprint requests to: Dr. Peter Ngan, Department of Orthodontics, West Virginia University, 1076 Health Science Center North, PO Box 9480, Morgantown, WV 26506.
Copyright © 1996 by the American Association of Orthodontists.
0889-5406/96/$5.00 + 0 8/1/63298

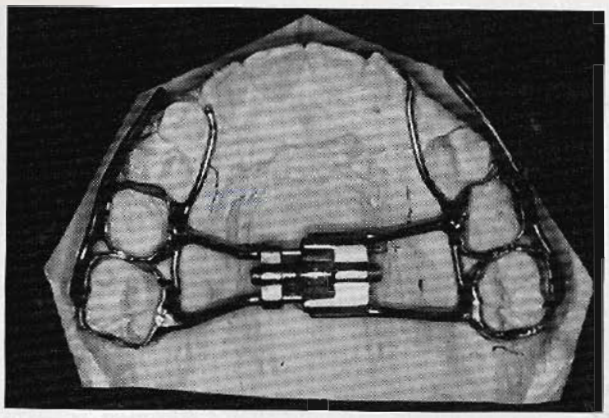

Fig. 1. Hyrax rapid palatal expansion appliance with wire soldered bilaterally to buccal aspects of molar bands and extended anteriorly to canine area for attachments of elastics to face mask.

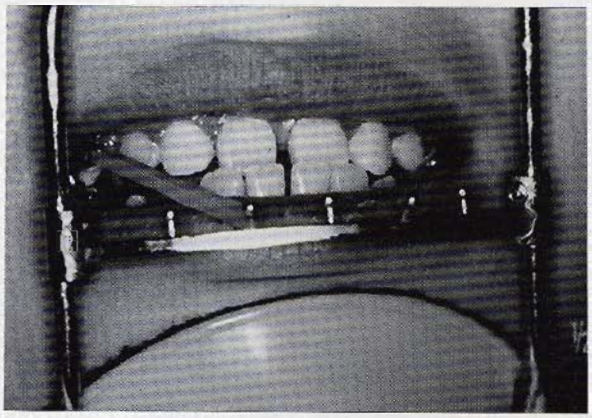

Fig. 2. Face mask with adjustable anterior hooks to effect downward and forward direction of elastic traction to maxilla.

by Bjork and Skieller[37] was found to be more appropriate for use in growing children by compensating for the growth changes that occurred in the structures on which the superimposition was performed.[38-40] Nielsen,[39] when comparing three maxillary superimposition techniques, found that the Bjork and Skieller technique[37] was the most accurate, and Doppel et al.[40] concurred with Bjork and Skieller[37] in their finding that the zygomatic process was the most stable structure for maxillary superimpositioning.

The objective of this study was (1) to determine the maxillary A point changes that occur during and after maxillary protraction treatment in 25 consecutively treated patients with Class III malocclusions and compare it to an untreated Class III control sample, and (2) to determine the relative skeletal and local remodeling contributions to the total A point change, using the Bjork and Skieller's method of cephalometric maxillary superimposition.

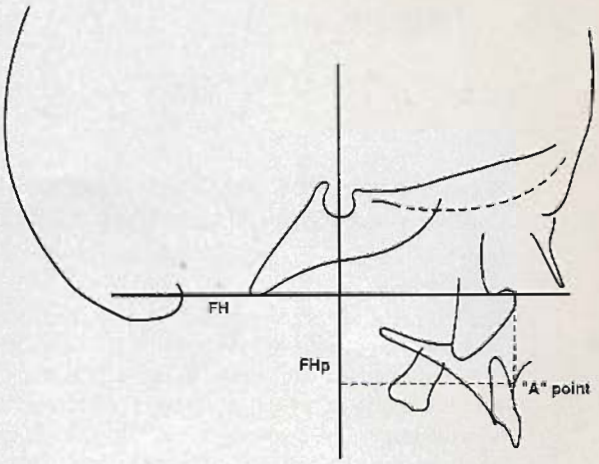

Fig. 3. Grid used for measuring total A point change. Frankfort Horizontal (FH) forms horizontal axis and perpendicular to FH through sella (FHp) forms vertical axis.

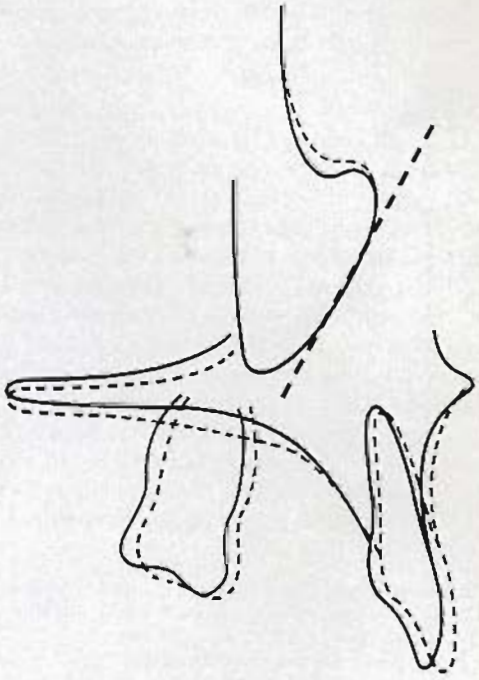

Fig. 4. Bjork and Skieller's "Structural Method" of maxillary superimposition.

MATERIALS AND METHODS

The experimental sample consisted of pretreatment and posttreatment lateral cephalometric radiographs of 25 Chinese children with Class III malocclusions who were treated with maxillary orthopedic expansion and protraction at the Department of Children's Dentistry and Orthodontics, University of Hong Kong. The group consisted of 9 boys and 16

girls with a mean age of 8.4 years (range = 6 to 12 years). These patients were examined and found to have skeletal Class III malocclusions with maxillary deficiency. Clinically, they all had a reverse overjet. None of the subjects had a history of previous orthodontic treatment. The control sample consisted of 25 untreated Chinese children with Class III malocclusions, who were matched for age, sex, and Class III structure with the experimental group.

Table I compared the pretreatment skeletal structures of the experimental and control groups. No significant differences were found in any of the cephalometric parameters tested.

Table I. Comparison of pretreatment characteristics of treatment ($n = 25$) and control ($n = 25$) groups

	Treatment group		*Control Group*		
	Mean	*SD*	*Mean*	*SD*	*Significance*
Age	8.4	1.92	8.6	1.87	NS
SNA	81.3	3.85	81.0	3.69	NS
SNB	81.3	3.18	81.4	3.01	NS
ANB	0.0	2.57	−0.3	2.67	NS
Maxillary length	77.6	3.94	78.6	3.94	NS
Mandibular length	104.0	5.57	106.0	6.27	NS
Maxillary-Mandibular difference	26.6	4.23	27.1	4.86	NS
Wits	−8.1	3.43	−9.7	3.54	NS
Mandibular plane angle	34.2	3.89	36.1	4.29	NS

Appliances for Class III Correction (Figs. 1 and 2)

The Hyrax rapid palatal expansion appliance was constructed with bands on the posterior teeth. The bands were joined by a heavy wire (0.045 inch) palatally, and buccally this wire was extended anteriorly to the canine area and fashioned as a hook to receive the protraction elastics.[41] The appliance was activated two turns a day (0.25 mm per turn) by the patient for 1 week.

The face mask used for protraction was a one-piece construction with adjustable anterior hooks for elastics. Approximately 400 gm of protraction force was delivered per side to the hooks in the canine region, with elastics adjusted to effect a downward and forward pull at 30° to the occlusal plane to minimize the counterclockwise rotation tendency.[22,42] The patients were instructed to wear the face mask for at least 12 hours a day, starting after the week of maxillary expansion. No form of retention was used at the completion of treatment.

Cephalometric Records

Cephalometric radiographs were taken for all experimental subjects at three time intervals, before treatment (T1), after 6 months of protraction treatment (T2), and 12 months after completion of protraction treatment (T3). Most of the subjects ($n = 19$) achieved the treatment objectives within 6 months of protraction therapy, including correction of reverse overjet and Class III molar relationship. In a few subjects ($n = 6$), continued maxillary protraction was needed until achievement of treatment objectives. For the control sample, serial cephalometric radiographs were available for the similar time intervals corresponding to the treatment and post-treatment periods of the experimental group. All the radiographs were taken with the same cephalometer. All tracings and measurements were made twice by the same operator, 2 months apart, and the values obtained were averaged to reduce measurement errors. All measurements were made up to 0.5 mm accuracy.

Cephalometric Error

Cephalometric radiographs of five experimental subjects and five control subjects were selected at random and traced three times, with 1 week between each tracing to determine the reliability of the measurements. A reliability coefficient (intraclass correlation coefficient) was calculated with a repeated-measures analysis of variance as shown in Table II.

Table II. Reliability coefficients indicating the reliability of the measurements of "A" point change

Variables	*Reliability coefficient*
Horizontal measurements	0.97
Vertical measurements	0.83
Horizontal measurements on maxillary superimposition	0.98
Vertical measurements on maxillary superimposition	0.77

Measurements on the Constructed Grid to Determine Total A Point Changes

The anatomic structures and cephalometric landmarks that were traced and the constructed grid used for making A point measurements are shown in Fig. 3. The grid was constructed on the first cephalogram, with the Frankfort's Horizontal (FH) as the horizontal axis and a line perpendicular to it, and passing through sella as the vertical axis. This grid was transferred to the T1, T2, and T3 tracings directly from the T1 cephalogram by superimposing on stable structures of the anterior cranial base.[41] Direct superimposition on the T1 cephalogram instead of on the T1 tracing has been reported to reduce errors.[43] Perpendicular distances from the horizontal and vertical axes of the grid to A point were measured. Horizontal measurements (H1, H2, and H3) of A point were made perpendicular to the vertical axis of the grid on the T1, T2, and T3 cephalograms, respectively. Vertical measurements (V1, V2, and V3) of A point were made perpendicular to the horizontal axis of the grid.

Maxillary Superimposition Technique to Differentiate Between Skeletal and Local Remodeling Changes

The Bjork and Skieller's technique of maxillary superimposition[37] was performed by superimposing tracings T2 on T1 and T3 on T2. The anterior contour of the zygomatic process was used as horizontal reference of superimposition and for the vertical reference the superimposed tracing was

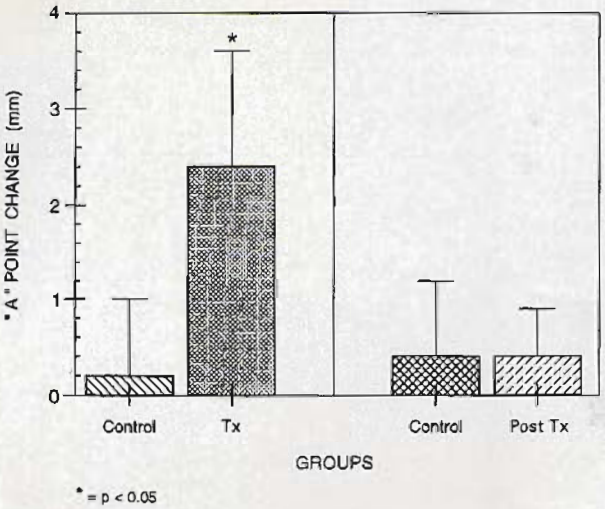

Fig. 5. Total horizontal A point changes.

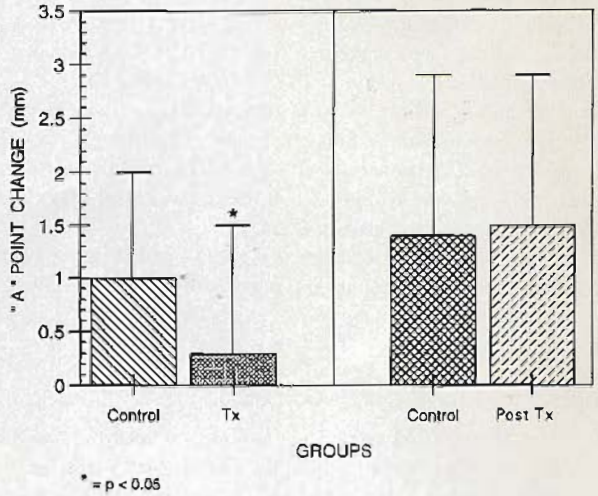

Fig. 6. Total vertical A point changes.

adjusted to show equal amounts of lowering of the nasal floor and raising of the orbital floor (Fig. 4). Bjork and Skieller[27] found no stable structure for vertical orientation but found that the amount of resorption on the nasal floor was almost equal to the amount of apposition on the orbital floor. The horizontal and vertical changes of A point, evident on superimposition, represented the local changes that resulted from localized remodeling.[41] Horizontal measurements, SH1 and SH2, of A point were made perpendicular to the vertical axis on the superimpositioned radiographs T1 and T2. Horizontal measurements, SH3 and SH4, were on the T2 and T3 superimposition radiographs. Vertical measurements, SV1 and SV2, of A point were made perpendicular to the horizontal axis on the superimpositioned radiographs T1 and T2. Vertical measurements, SV3 and SV4, were on the T2 and T3 superimposition radiographs.

Calculation of A Point Changes During Treatment (T1-T2) and After Treatment (T2-T3)

The difference in the horizontal and vertical measurements of A point from H1 to H2 (ΔH1) and V1 to V2 (ΔV1) and from H2 and H3 (ΔH2) and V2 to V3 (ΔV2) were calculated. Similar differences ΔSH1, ΔSV1, ΔSH2, and ΔSV2 were calculated for the superimpositioned tracings. These values represented the calculated changes between the time periods (T1-T2 and T3-T4) in horizontal and vertical A point position (Table III).

Calculation of Skeletal and Local Remodeling Contributions to Total A Point Changes

A point changes measured with the constructed grid represented the total A point changes. A point changes measured by the superimposition method represented the local remodeling changes. The skeletal contributions to the A point change were calculated by subtracting the local from the total measured A point changes (Table IV).

Statistical Analysis

The mean values for the variables ΔH1, ΔV1, ΔH2, ΔV2, ΔSH1, ΔSV1, ΔSH2, and ΔSV2 were calculated for the treated and control groups. Between group differences for all the variables were analyzed with a multivariate analysis of variance and independent *t* test.

RESULTS

The reliability coefficients calculated for the different measurements of A point change are presented in Table II.

Total Horizontal and Vertical Changes (Table III, Figs. 5 and 6)

Significantly greater forward movement of A point was found with treatment when compared with the control group (ΔH1 = 2.4 mm vs 0.2 mm, $p < 0.001$). Significantly less downward movement of A point was found with treatment when compared with the control group (ΔV1 = 0.3 mm vs 1.0 mm, $p < 0.05$).

No significant difference was found in the forward movement of A point between the treatment group during the 12-month posttreatment observation period when compared with the control group for a similar period (ΔH2 = 0.4 mm in both groups). No significant difference was found in the downward movement of A point between the treatment and control groups for the same time period (ΔV2 = 1.5 mm vs 1.4 mm).

Local Horizontal and Vertical A point Remodeling Changes (Table III, Figs. 7 and 8)

A significant difference was found in the local horizontal A point change (ΔSH1) between the treatment group during treatment, and the control group ($p < 0.001$). A point was found to remodel forward 0.6

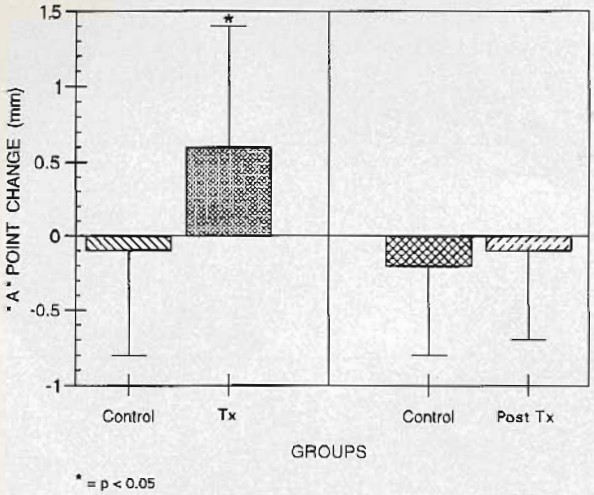

Fig. 7. Local horizontal A point changes.

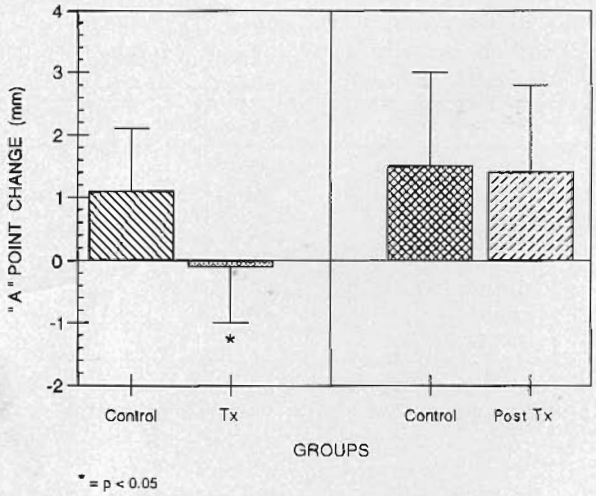

Fig. 8. Local vertical A point changes.

mm in the treatment group and backward 0.1 mm in the control group. A significant difference was also found in the local vertical A point change (ΔSV1) between the treatment group during treatment and the control group ($p < 0.001$). A point was found to remodel upward 0.1 mm in the treatment group and downward 1.1 mm in the control group.

No significant difference was found between the local horizontal and vertical A point change in the treatment group during the 12-month posttreatment observation period and the control group for the same period of time (ΔSH2 = –0.1 mm vs –0.2 mm and ΔSV2 = 1.4 mm vs 1.5 mm). In both groups, A point was found to remodel backward and downward.

The local remodeling and skeletal contributions to the total A point change are presented in Table IV. During treatment 75% of the total forward movement of A point (1.8 mm of 2.4 mm) was due to skeletal maxillary protraction and 25% (0.6 mm of 2.4 mm) was due to localized remodeling.

DISCUSSION

Control Sample

In the few maxillary protraction studies that had included a control sample, the experimental subjects were compared with control subjects with normal maxillomandibular skeletal relations.[6,8,9,24] In this study the control sample consisted of subjects who were closely matched for age, sex, and Class III structure with the treated sample (Table I). In this study A point was found to advance 0.2 mm in 6 months in the untreated Class III control sample. This is in contrast to the Tindlund et al.[8] and Takada et al.[24] studies in which A point in the Class I control subjects was found to advance 0.8 mm and 0.7 mm in 12 months, respectively. This clearly illustrates the advantage of using a Class III control sample for making valid comparisons.

Cephalometric Error

Random errors are known to occur because of variations in the radiographic technique, however, with careful technique it has been shown to be small and negligible.[44,45] The largest source of error in cephalometric tracing has been shown to be from imprecision in landmark identification. Recommendations made for reducing these errors include the use of high quality radiographs and replication and averaging of all measurements.[35,46] In this study all radiographs were traced twice 2 months apart by the same operator and the measurements were averaged. The reliability coefficient for the horizontal measurements of both the total and local A point changes was found to be high (>0.9). The reliability coefficient for measurements of the total vertical A point changes was considered acceptable (0.83). However, the reliability coefficient for the local vertical change was only 0.77. This could be attributed to the superimposition technique, where the vertical orientation for superimposition involved a subjective process of bisecting changes at the orbit and nasal floor.

Treatment Changes

In this study, 6 months of maxillary protraction preceded by maxillary expansion resulted in an average A point advancement of 2.4 mm. Before comparing these results with others reported in the literature, the major variables in the different studies that could have influenced the treatment response should first be

Table III. Total horizontal and vertical "A" point changes during treatment (ΔH1, ΔV1) and posttreatment periods (ΔH2, ΔV2). "A" point changes because of local remodeling during treatment (ΔSH1, ΔSV1) and posttreatment periods (ΔSH2, ΔSV2)

Variable	*Treatment group*	*SD*	*Control group*	*SD*	*p value*
ΔH1	2.4	1.2	0.2	0.8	0.000
ΔH2	0.4	0.6	0.4	0.8	1.000
ΔV1	0.3	1.3	1.0	1.0	0.017
ΔV2	1.5	1.4	1.4	1.5	0.800
ΔSH1	0.6	0.8	−0.1	0.6	0.001
ΔSH2	−0.1	0.6	−0.2	0.6	0.650
ΔSV1	−0.1	0.9	1.1	1.0	0.000
ΔSV2	1.4	1.4	1.5	1.5	0.960

For horizontal measurements, negative values indicate backward movement and positive values forward movement.
For vertical measurements, negative values indicate upward movement and positive values downward movement.

Table IV. Local and skeletal contributions to total "A" point changes

	Local Remodeling changes		*Skeletal changes*		*Total "A" point changes (local and skeletal)*
	Mean (mm)	*% total*	*Mean (mm)*	*% total*	*Mean (mm)*
Horizontal changes					
Control	−0.1	−50	0.3	150	0.2
Treatment	0.6	25	1.8	75	2.4
Control	−0.2	−50	0.6	150	0.4
Posttreatment	−0.1	−25	0.5	125	0.4
Vertical changes					
Control	1.1	110	−0.1	−10	1.0
Treatment	−0.1	−33	0.4	133	0.3
Control	1.5	107	−0.1	−7	1.4
Posttreatment	1.4	93	0.1	7	1.5

For horizontal changes, negative values represent backward movement; positive values represent forward movement.
For vertical changes, negative values represent upward movement; positive values represent downward movement.

considered. These include the age of the patients, the use of maxillary expansion in conjunction with protraction, and the use of protraction on patients with repaired cleft palates. Tindlund et al.[8] reported an A point advancement of 1.3 mm in patients with cleft palate with 13 months of protraction preceded by maxillary expansion. Ishii et al.[6] reported an increase in maxillary length of 2.7 mm in noncleft patients protracted for 16 months with no maxillary expansion. Takada et al.[24] examined the effect of age on maxillary protraction and found a definite advantage in treating children in the prepubertal period, where 2.2 mm of increase in maxillary length was obtained in 13 months of maxillary protraction with no expansion. The results achieved in this study compare favorably with others reported and the protraction was achieved in half the time. This may be attributed to the reported beneficial effects of orthopedic maxillary expansion before protraction in accelerating protraction by "loosening of the circum-maxillary sutures."[14-16]

Vertical A point change was a 0.3 mm downward movement in the treatment group compared with 1.0 mm downward movement in the control group. Therefore treatment appears to inhibit the normal downward movement of A point. This may be the result of the reported counterclockwise rotation of the maxilla as a result of the protraction forces.[6,8,9,24,42,47]

The maxillary superimposition technique used in this study resulted in the estimation of the local and skeletal contributions to the total A point change that so far has not been reported. In the treatment group the localized changes resulted in the forward movement of A point of 0.6 mm. This was probably the result of forward movement of maxillary incisors that has been reported with maxillary protraction.[6,8,17,22] In the control group local remodeling changes caused A point to move backward by 0.1 mm, indicating that this area was resorptive as reported in the publications.[48]

In the treatment group local remodeling changes produced a 0.1 mm upward movement of A point, which was too small a change to be of any significance. In the control group local remodeling changes were found to cause a 1.1 mm downward movement of A point. This seems unlikely considering that the total downward movement of A point was only 1.0 mm. This would mean that the skeletal contribution would

have to be in an upward direction. One reason for this discrepancy could be related to the Bjork and Skieller's technique[37] that assumed an equal ratio of orbital floor raising and palatal floor lowering with growth in the superimposition. Doppel et al.[40] found that the ratio was 1.5 to 1.0 in favor of raising of the orbital floor. This discrepancy could have resulted in the overestimation of the local vertical change. This combined with the lower correlation coefficient for reliability of measurements of this dimension, calls for caution in interpreting the results in this dimension.

Posttreatment Changes

One year after cessation of protraction forces, A point moved downward and forward by similar amounts in both the control and treatment groups, indicating that maxillary growth in the treated group reverted to the control level. More significantly, the results showed that there was no relapse in the achieved forward movement of the maxilla, even without the use of any retention devices.

In examining the local remodeling changes in A point during the posttreatment period, no significant difference was found between the treatment and the control groups, indicating a return to control group pattern of local remodeling activity.

Individual Variations

The high standard deviation values for measurements in both the control and treatment groups indicate individual variability in growth and treatment. Individuality in patients facial skeletal growth pattern has been documented in the literature reference.[49] In this study, variability in treatment response is shown with maxillary protraction. Clinicians should be aware that the mean values are indicative of the trends discussed thus far, the importance of individual variability as it relates to treatment response should be acknowledged. A point advancement in this sample, ranged from 0 to 4.5 mm for the 6-month period of treatment. It is our opinion that additional factors like the age of patients' skeletal pattern, the person's growth potential, and patient cooperation are significant factors that influence the treatment outcome.

CONCLUSIONS

1. Maxillary protraction treatment during the deciduous and mixed-dentition period resulted in a significantly greater forward movement of A point during the 6 months of treatment compared with untreated controls.
2. Of A point advancement, 75% was the result of skeletal maxillary advancement and 25% was due to local remodeling changes.
3. The amount of vertical and horizontal movement of A point could be related to the direction of force application. The amount of local remodeling could be related to the incisal movement.
4. During the 12-month posttreatment follow-up period no relapse of achieved maxillary changes was noted in the treatment group and the estimated maxillary changes resembled those of the control group.

REFERENCES

1. Irie M, Nakamura S. Orthopedic approach to severe skeletal Class III malocclusion. Am J Orthod 1975;67:377-92.
2. Graber LW. Chincup therapy for mandibular prognathism. Am J Orthod 1977;72:23-41.
3. Petit H. Adaptations following accelerated facial mask therapy. In: McNamara JA, Ribbens KA, Howe RP, eds. Clinical alteration of the growing face. Monograph 14, Craniofacial Growth Series. Ann Arbor: Center for human growth and development, University of Michigan, 1983.
4. Mitani H, Sakamato T. Chin cap force to growing mandible: long-term clinical reports. Angle Orthod 1984;54:93-122.
5. Sarnas KV, Rune B. Extraoral traction to the maxilla with the facemask: a follow-up of 17 consecutively treated patients with and without cleft lip and palate. Cleft Palate J 1987;24:95-103.
6. Ishii H, Morita S, Takeuchi Y, et al. Treatment effect of combined maxillary protraction appliance and chincap appliance in severe skeletal Class III cases. Am J Orthod Dentofacial Orthop 1987;92:304-12.
7. Sugawara J, Asano T, Endo N, et al. Long-term effects of chincap on skeletal profile in mandibular prognathism. Am J Orthod Dentofacial Orthop 1990;98:127-33.
8. Tindlund RS, Rygh P, Boe OE. Orthopedic protraction of the upper jaw in cleft lip and palate patients during the deciduous and mixed dentition periods in comparison with normal growth and development. Cleft Palate-Craniofacial J 1993;30:182-94.
9. Wisth PJ, Tritrapunt A, Rygh P, et al. The effect of maxillary protraction on front occlusion and facial morphology. Acta Odontol Scand 1987;45:227-37.
10. Dellinger EL. A preliminary study of anterior maxillary displacement. Am J Orthod 1973;63:509-16.
11. Kambara T. Dentofacial changes produced by extraoral forward force in Macaca irus. Am J Orthod 1977;71:249-77.
12. Nanda R. Protraction of maxilla in rhesus monkeys by controlled extraoral forces. Am J Orthod 1978;74:121-41.
13. Jackson GW, Kokich VG, Shapiro PA. Experimental response to anteriorly directed extraoral force in young Macaca nemestrina. Am J Orthod 1979;75:319-33.
14. Haas AJ. Palatal expansion: just the beginning of dentofacial orthopedics. Am J Orthod 1975;57:219-55.
15. McNamara JA. An orthopedic approach to the treatment of Class III malocclusion in young patients. J Clin Orthod 1987;21:598-608.
16. Turley P. Orthopedic correction of Class III malocclusion with palatal expansion and custom protraction headgear. J Clin Orthod 1988;22:314-25.
17. Ngan P, Wei SHY, Yiu CKY, et al. Effect of protraction headgear on Class III malocclusion. Quintessence Int 1992;23:197-207.
18. Cooke MS, Wreakes G. The facemask: a new form of reverse headgear. Br J Orthod 1977;4:163-8.
19. Cozzani G. Extraoral traction and Class III treatment. Am J Orthod 1981;80:638-50.
20. Delaire J. L'articulation fronto-maxillaire: bases theoretique et principles genereux d'application de forces extra-oral postero-anterieures sur masque orthopedique. Rev Stomat Paris 1976;77:921-30.
21. Nanda R. Biomechanical and clinical considerations of a modified protraction headgear. Am J Orthod 1980;78:125-39.
22. Tanne K, Sakuda M. Biomechanical and clinical changes of the craniofacial complex from orthopedic maxillary protraction. Angle Orthod 1991;61:145-52.
23. Tindlund RS. Orthopedic protraction of the midface in the deciduous dentition—results covering 3 years out of treatment. J Craniomaxillofac Surg 1989;17(Suppl 1):17-9.
24. Takada K, Petdachai S, Sakuda M. Changes in dentofacial morphology in skeletal Class III children treated by a modified protraction headgear and a chin cup: a longitudinal cephalometric appraisal. Eur J Orthod 1993;15:211-21.
25. Stenslund A, Wisth PJ, Boe OE. Dentofacial changes in children with negative overjet treated by a combined orthodontic and orthopedic approach. Eur J Orthod 1988;10:39-51.
26. Sanborn RT. Differences between the facial skeletal patterns of Class III malocclusion and normal occlusion. Angle Orthod 1955;25:208-22.
27. Dietrich UC. Morphologic variability of the skeletal Class III relationship as revealed by cephalometric analysis. Trans Eur Orthod Soc 1970:131-43.
28. Jacobson A, Evans WG, Preston CB, et al. Mandibular prognathism. Am J Orthod 1974;66:140-71.
29. Ellis E, McNamara JA. Components of adult Class III malocclusion. J Oral Max Surgery 1984;42:295-305.
30. Guyer EC, Ellis EE, McNamara JA, et al. Components of Class III malocclusion in juveniles and adolescents. Angle Orthod 1986;56:7-30.
31. Williams S, Andersen CE. The morphology of the potential Class III skeletal pattern in the young child. Am J Orthod 1986;89:302-11.
32. Chang H, Kinoshita Z, Kawamoto T. Craniofacial pattern of Class III deciduous dentition. Angle Orthod 1992;62:139-44.

33. Battagel JM. The etiological factors in Class III malocclusion. Eur J Orthod 1993;15:347-70.
34. Smalley WM, Shapiro PA, Hohl TH, et al. Osseointegrated titanium implants for maxillofacial protraction in monkeys. Am J Orthod Dentofacial Orthop 1988;94:285-95.
35. Houston WJB. The analysis of errors in orthodontic measurements. Am J Orthod 1983;83:382-90.
36. Baumrind S, Korn EL, Isaacson RJ, et al. Quantitative analysis of the orthodontic and orthopedic effects of maxillary traction. Am J Orthod 1983;84:384-98.
37. Bjork A, Skieller V. Roentgencephalometric growth analysis of the maxilla. Trans Eur Orthod Soc 1977;7:209-33.
38. Baumrind S, Korn EL, Ben-Bassat Y, et al. Quantification of maxillary remodeling: 1, a description of osseous changes relative to superimposition on metallic implants. Am J Orthod Dentofacial Orthop 1987;91:29-41.
39. Nielsen IL. Maxillary superimposition: a comparison of three methods for cephalometric evaluation of growth and treatment change. Am J Orthod Dentofacial Orthop 1989;95:422-31.
40. Doppel DM, Damon WM, Joondeph DR, et al. An investigation of maxillary superimposition techniques using metallic implants. Am J Orthod Dentofacial Orthop 1994;105:161-8.
41. Shanker S. A Cephalometric evaluation of maxillary changes during and after maxillary protraction therapy. [Master Thesis.] Columbus: The Ohio State University, 1994.
42. Itoh T, Chaconas SJ, Caputo AA, et al. Photoelastic effects of maxillary protraction on the craniofacial complex. Am J Orthod 1985;88:117-24.
43. Buschang PH, LaPalme L, Tanguay R, et al. The technical reliability of superimposition on the cranial base and mandibular structures. Eur J Orthod 1986;8:152-6.
44. Mitgard J, Bjork G, Linder-Aronson S. Reproducibility of cephalometric landmarks and errors of measurement of cephalometric cranial distances. Angle Orthod 1974;44:55-61.
45. Houston WJB, Maher R.E, McElroy D, et al. Sources of error in measurements from cephalometric radiographs. Eur J Orthod 1986;8:149-51.
46. Baumrind S, Frantz R. The reliability of head film measurements: 1, landmark identification. Am J Orthod 1971;60:111-27.
47. Hata S, Itoh T, Nakagawa K, et al. Biomechanical effects of maxillary protraction on the craniofacial complex. Am J Orthod 1987;91:305-11.
48. Enlow DH, Bang S. Growth and remodeling of the human maxilla. Am J Orthod 1965;51:446-64.
49. Thompson JR. The individuality of the patient in facial skeletal growth: part 2. Am J Orthod Dentofac Orthop 1994;105:117-27.

ON THE MOVE?

Send us your new address at least six weeks ahead

Don't miss a single issue of the journal! To ensure prompt service when you change your address, please photocopy and complete the form below.

Please send your change of address notification at least six weeks before your move to ensure continued service. We regret we cannot guarantee replacement of issues missed due to late notification.

JOURNAL TITLE:
Fill in the title of the journal here. _____

OLD ADDRESS:
Affix the address label from a recent issue of the journal here.

NEW ADDRESS:
Clearly print your new address here.

Name _____

Address _____

City/State/ZIP _____

COPY AND MAIL THIS FORM TO:
Journal Subscription Services
Mosby–Year Book, Inc.
11830 Westline Industrial Dr.
St. Louis, MO 63146-3318

OR FAX TO:
314-432-1158

Mosby

OR PHONE:
1-800-453-4351
Outside the U.S., call
314-453-4351